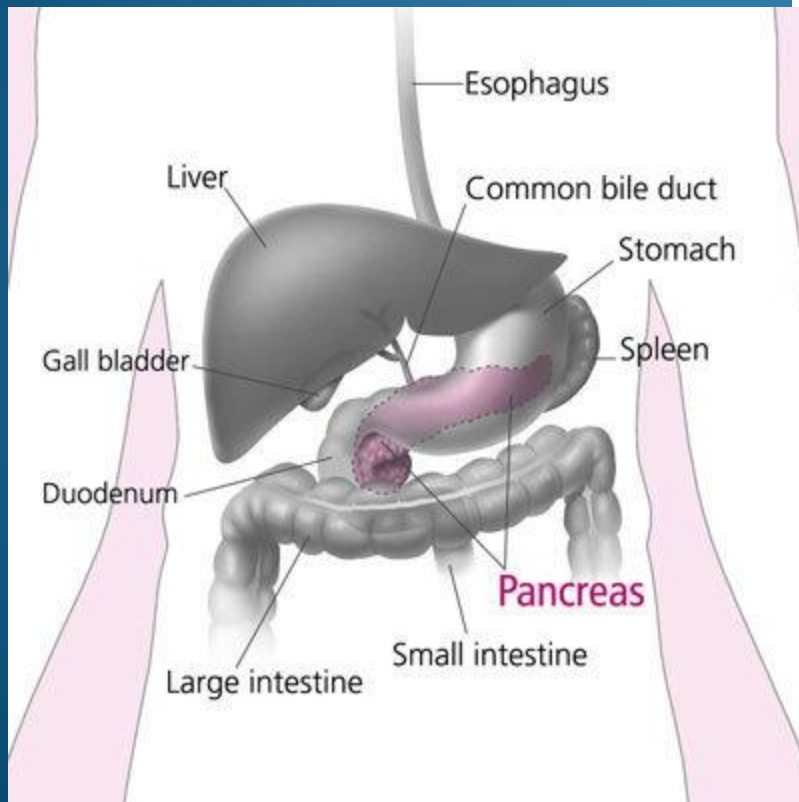
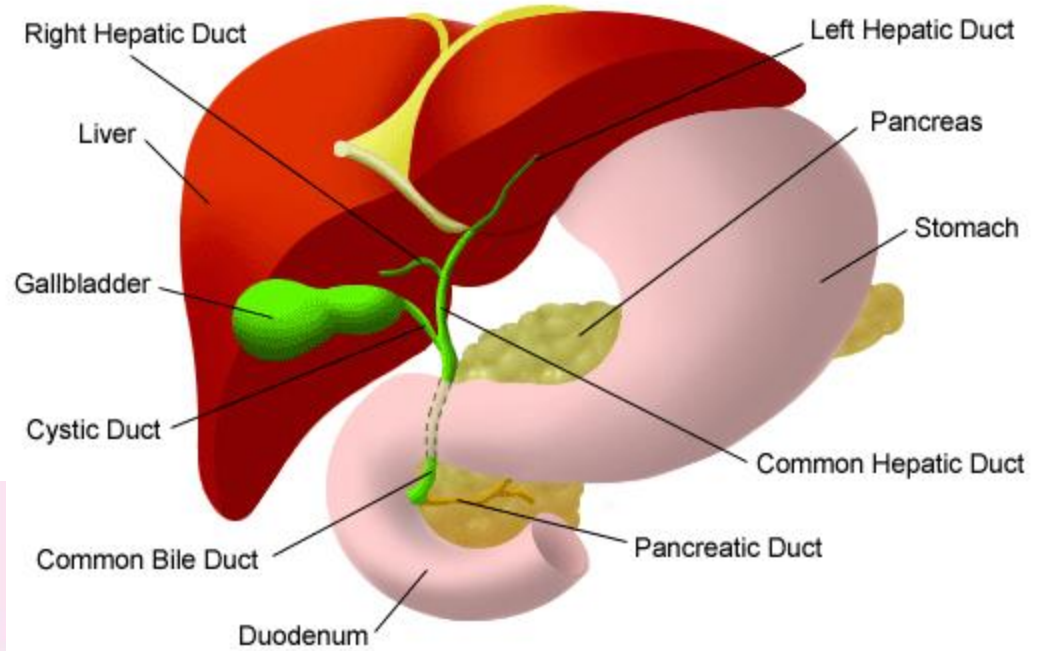
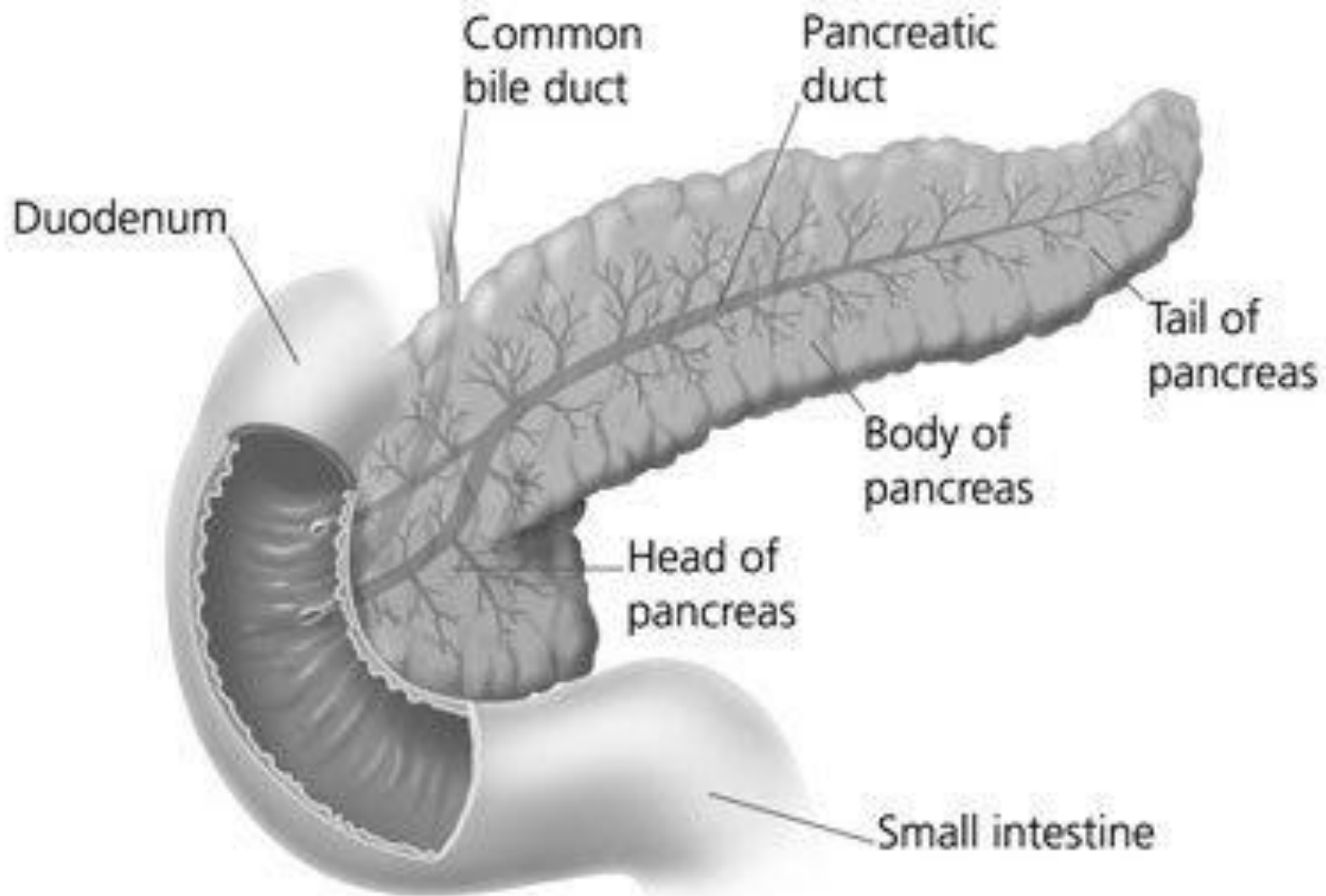


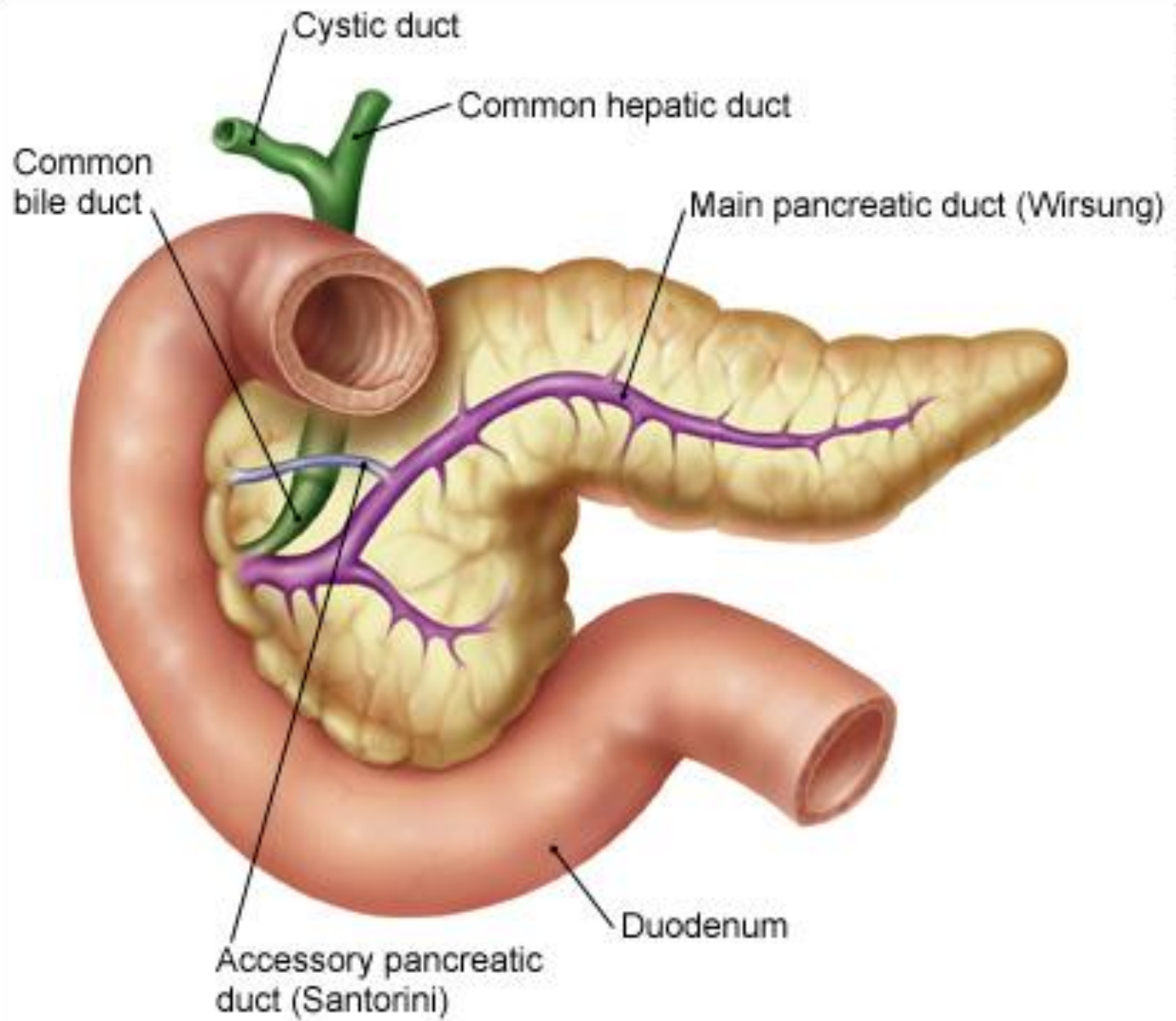
# The pancreas

**Pr. M. BILAL**

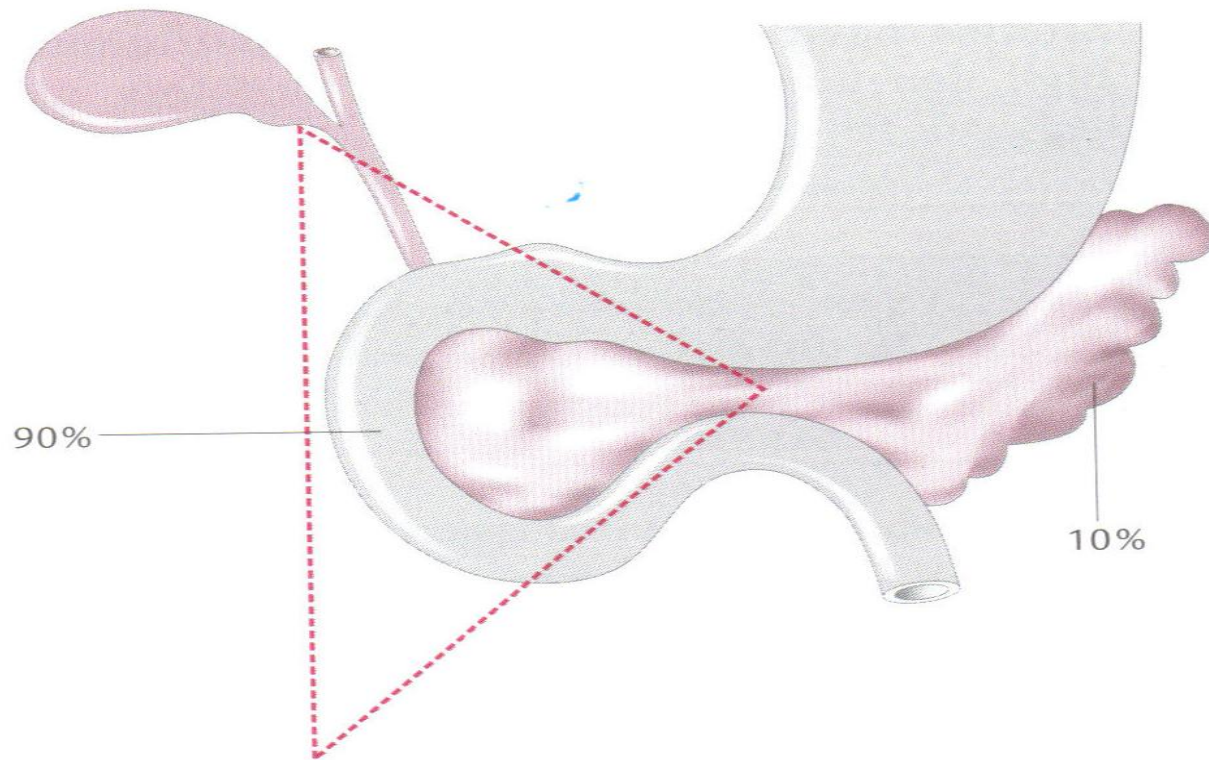
## Biliary System







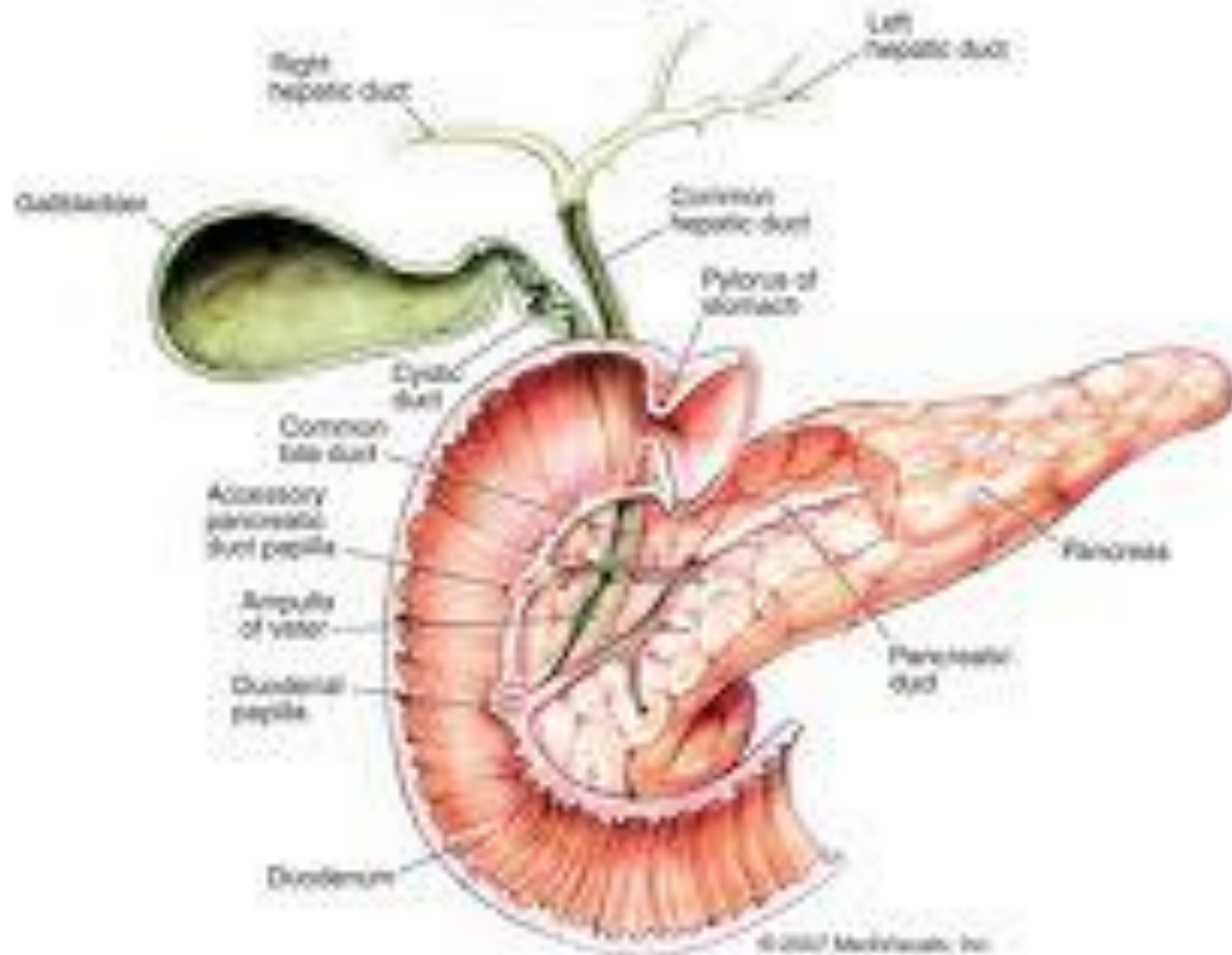
# Anatomy of the pancreas

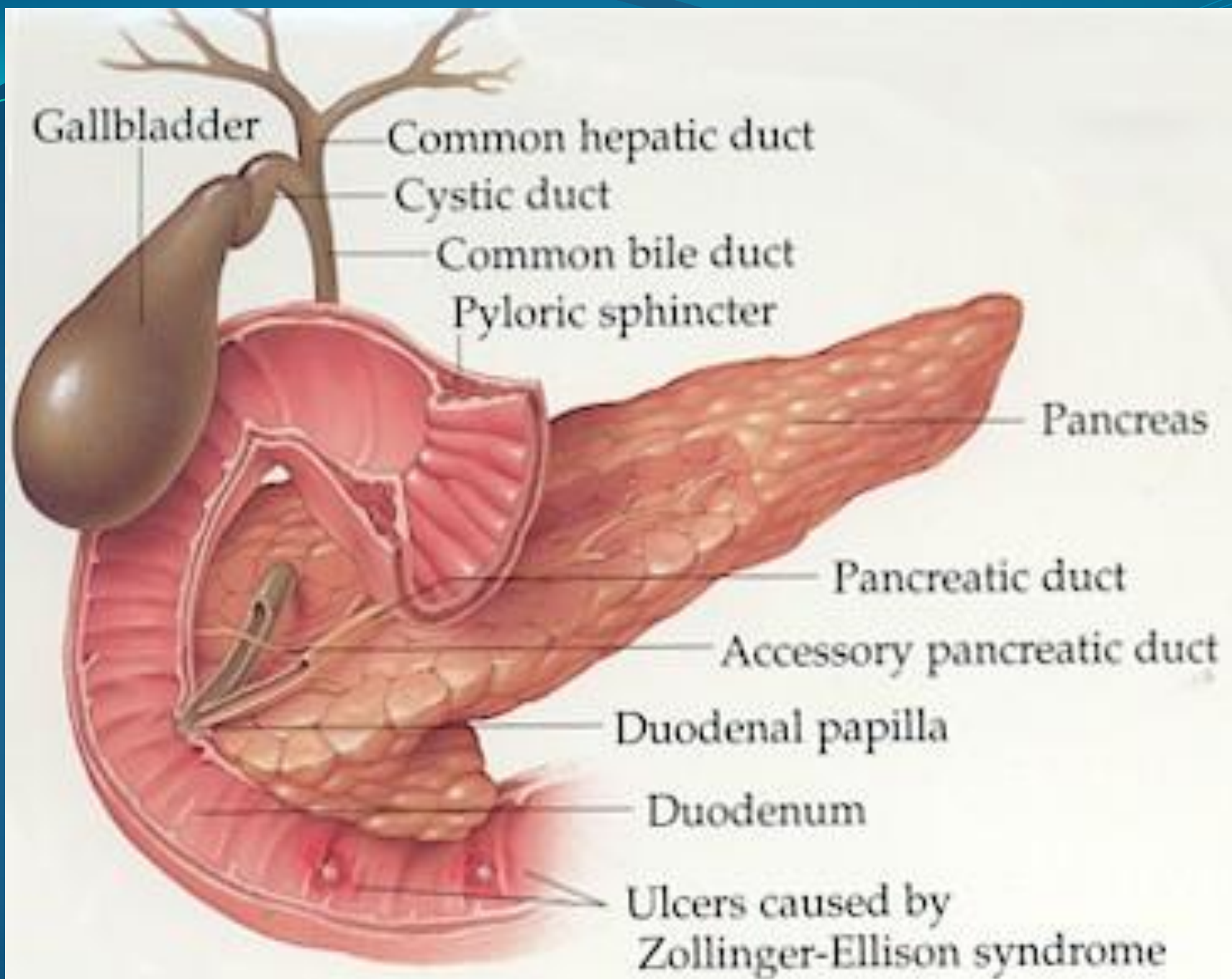


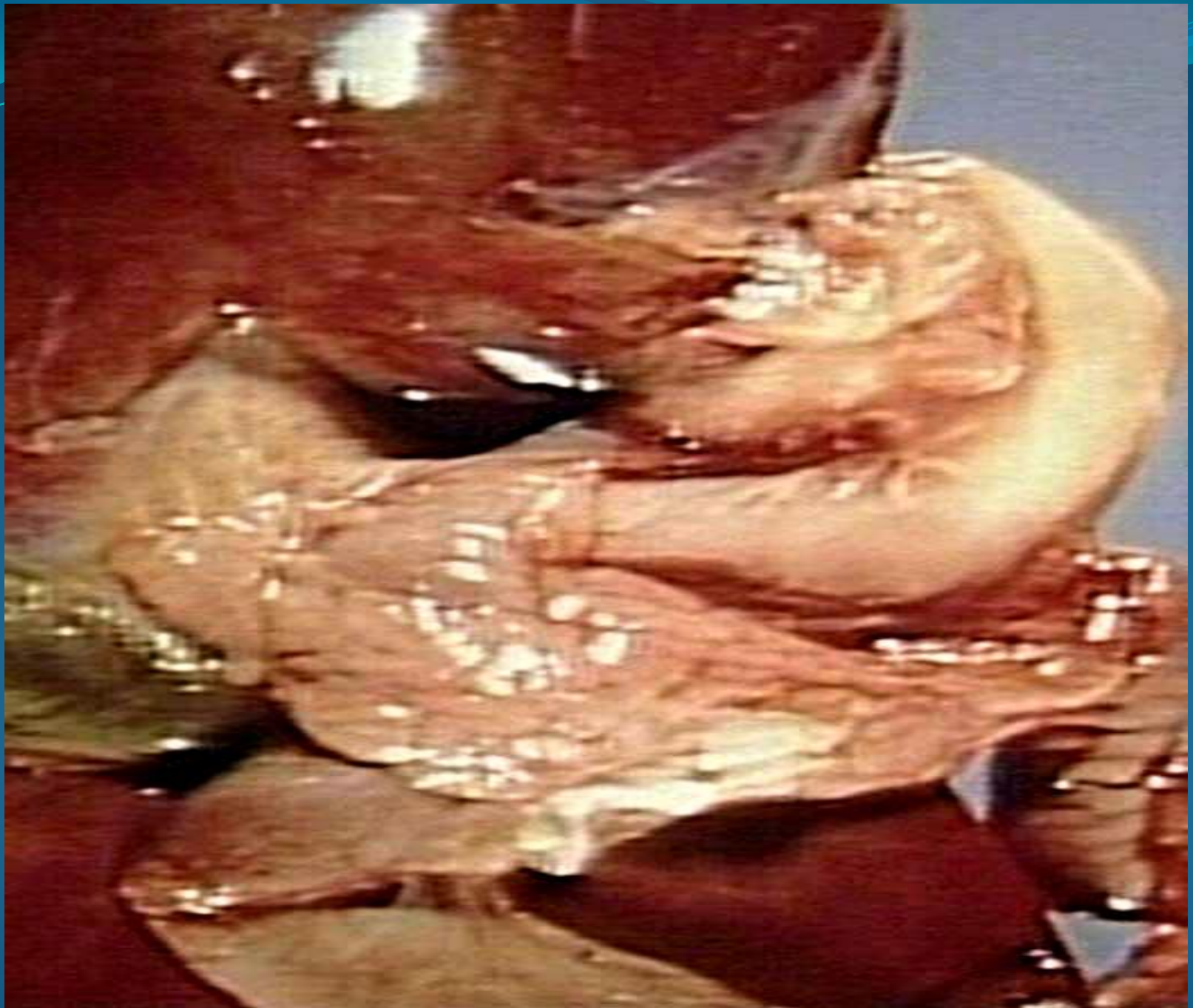
**Figure 23.2** Anatomic triangle in which gastrinomas are most often found. (From Mozzell et al.<sup>13</sup>)



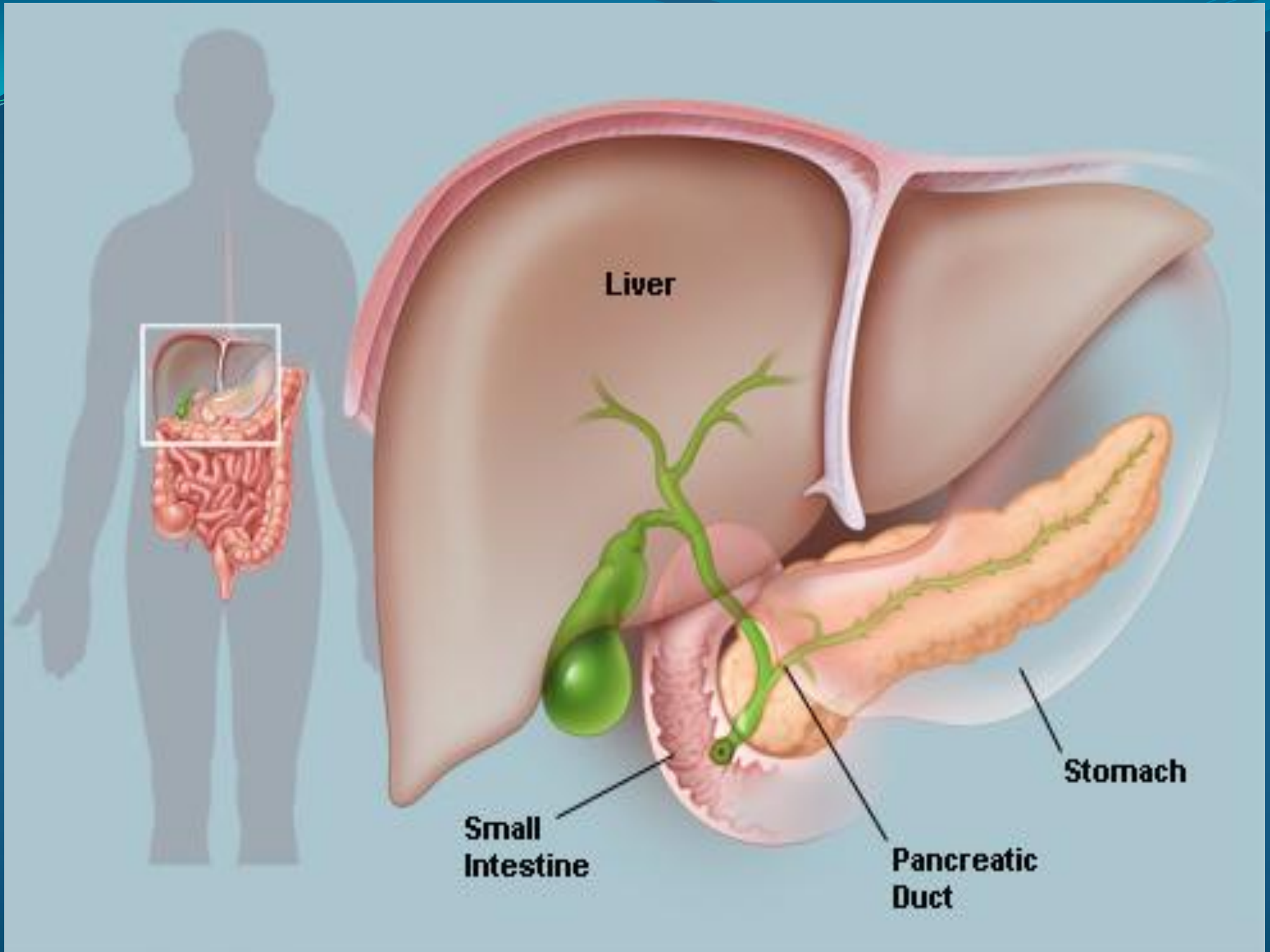
## The Biliary Tree











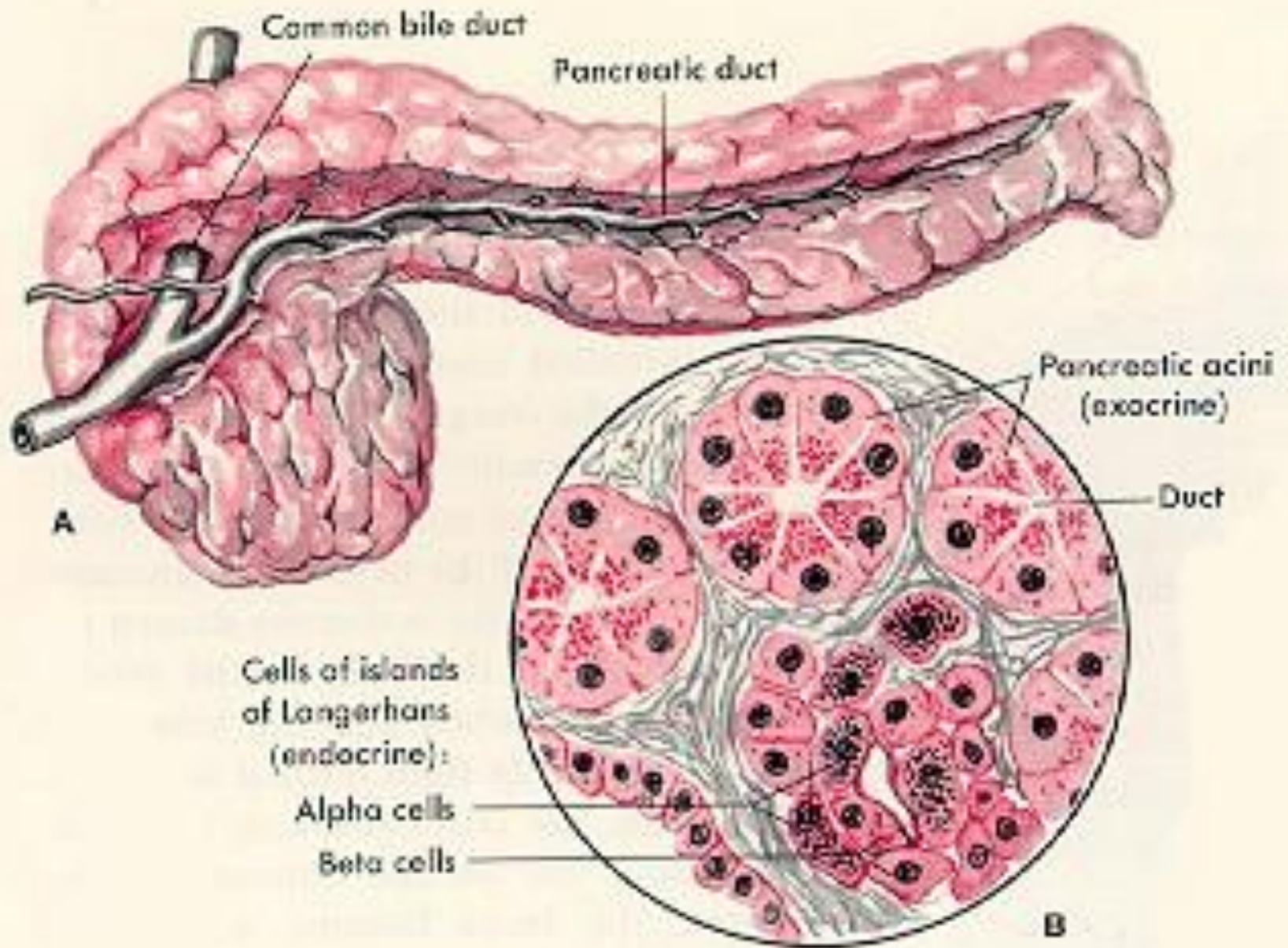
# physiology

**Endocrine function**( Insulin,glucagon,  
Somatostatin,Pancreatic polypeptide)

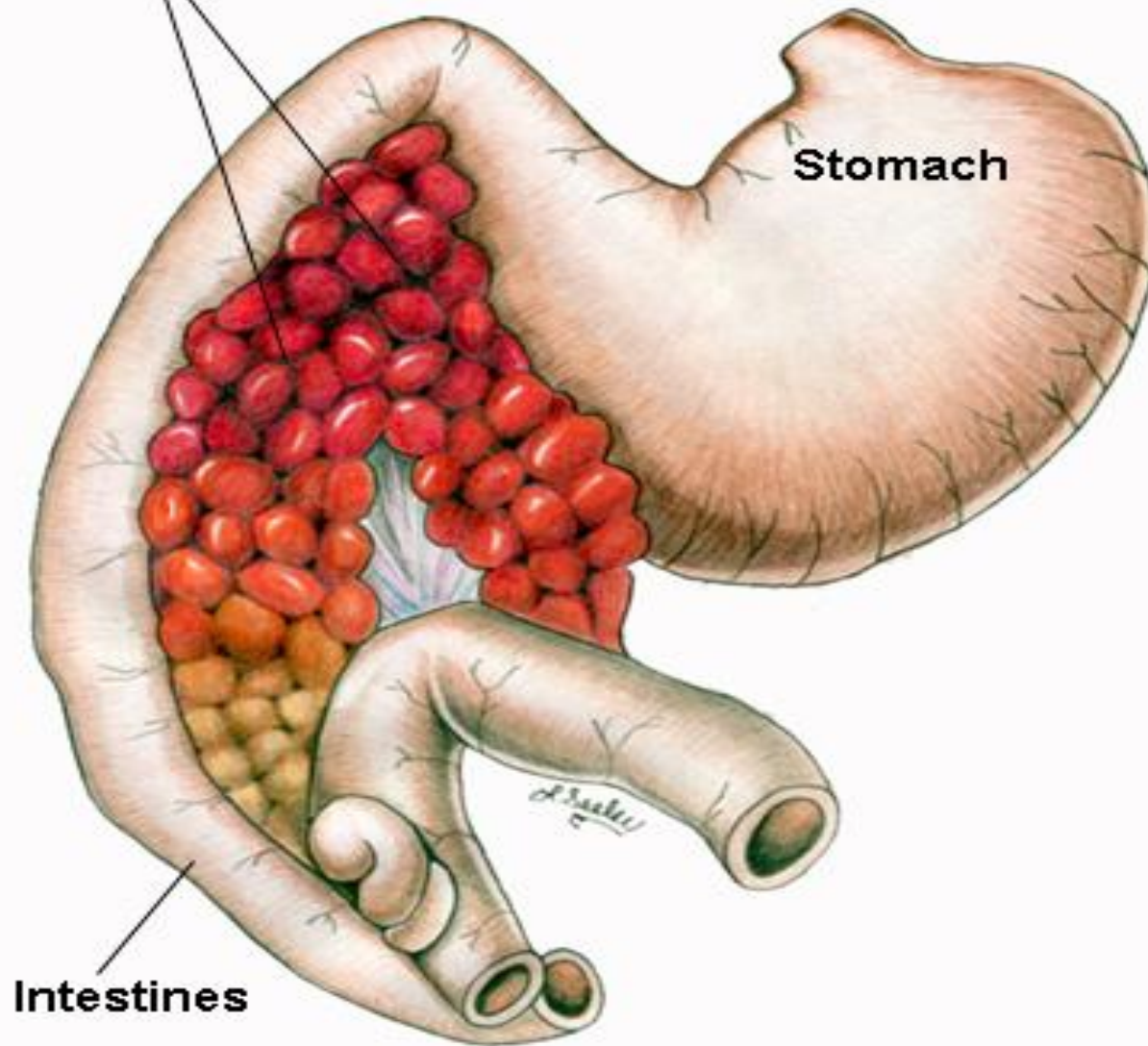
**Exocrine function**

**Enzyme secretion**

**Bicarbonate secretion**



# Pancreatitis





# Acute pancreatitis

## Etiology and pathophysiology :

Alcohol

Gallstones

Hyperlipidemia

Trauma

infection

Drugs

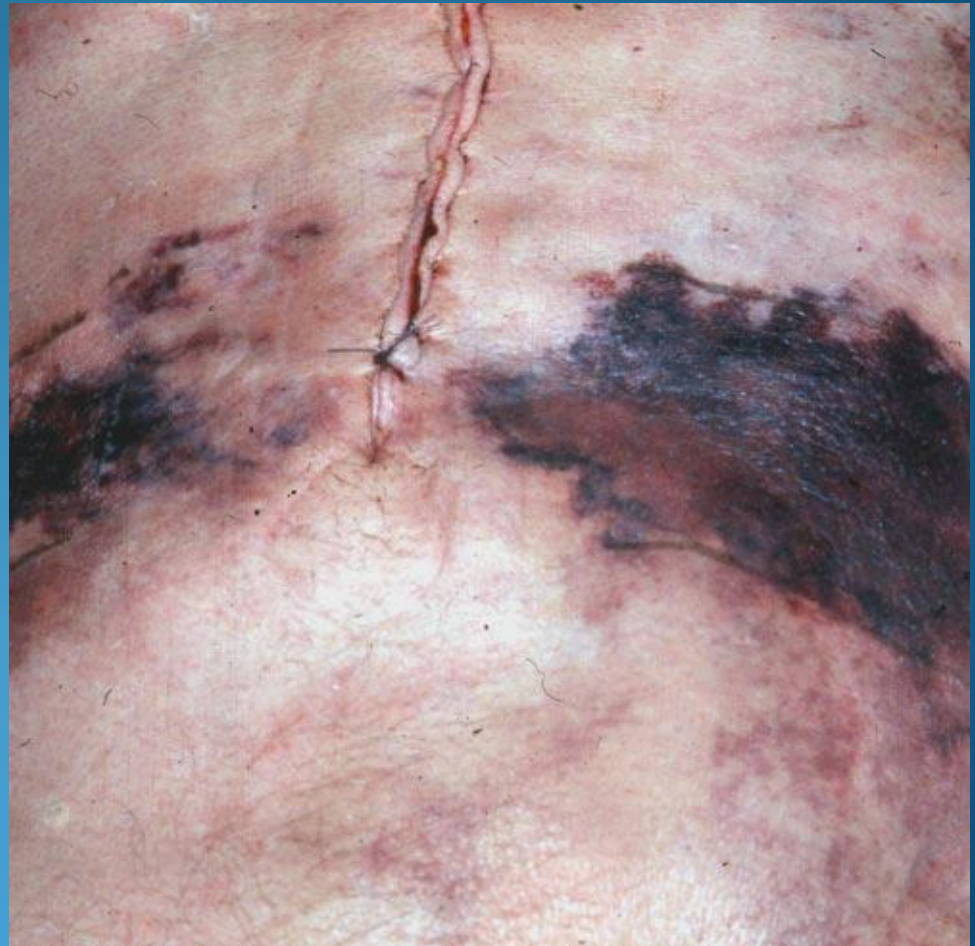Vasculitis and vascular insufficiency

Miscellaneous causes

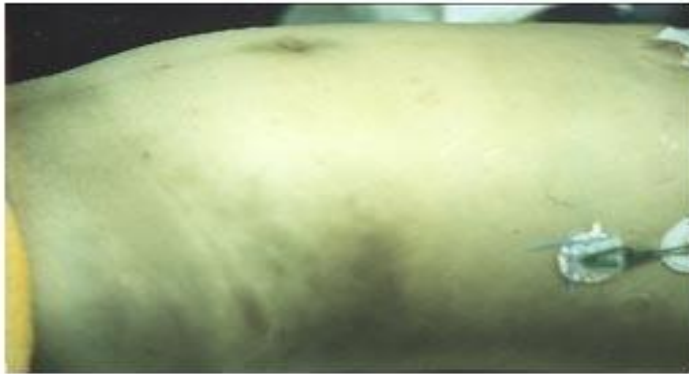
# Symptoms :

**Pain** is nearly always the presenting complaint and may be epigastric , lower abdominal , or localized to the posterior thoracic or lumbar area . the pain may be noted in the right or left hypochondrium or diffusely present throughout the entire abdomen , and may be mild or severe , but is usually steady and not cramping in nature . **nausea and vomiting** frequently occur and **anorexia** is common . **Low-grade fever** may accompany these symptoms , and **mild hypertension** is commonly seen unless **dehydration or hypovolemia** is present . frequently, these symptoms have occurred 1 to 3 days after a bout of heavy alcohol ingestion .

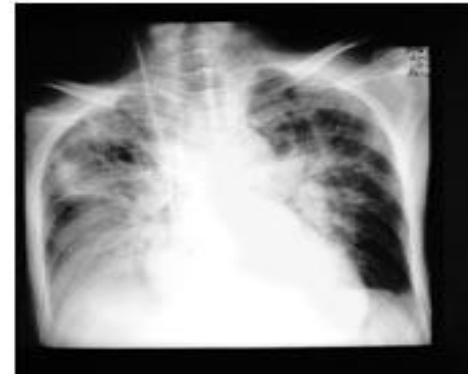This is Grey-Turner's sign with haemorrhage appearing in both flanks. It is due to extensive retro-peritoneal bleeding and typically occurs in haemorrhagic pancreatitis



# Acute Necrotizing Pancreatitis 急性壞死性胰炎



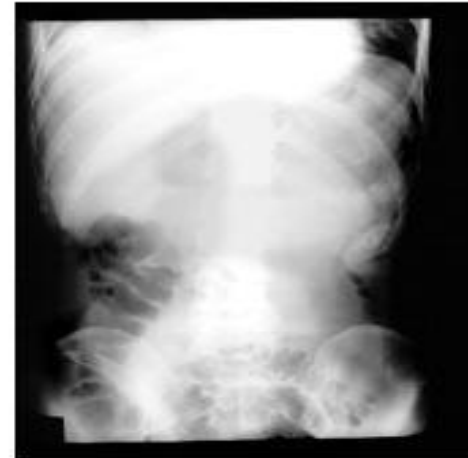
**Cullen's sign (periumbilical hemorrhage)  
Gray-Turner's sign (flank hemorrhage)**



**chest X-P showing ARDS**



**resected specimen showing the necrotic pancreas**



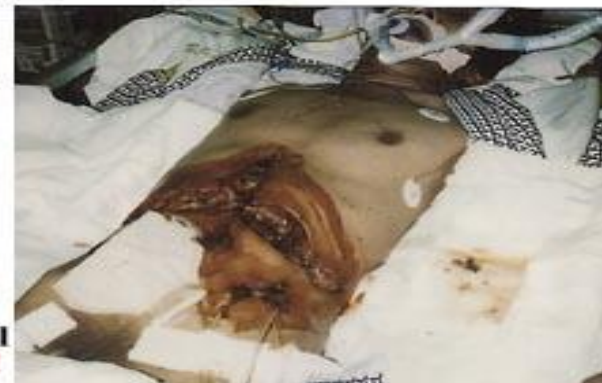**abdominal X-P with colon "cut-off"**



**infected peripancreatic necrotic tissues  
removed during drainage surgery**

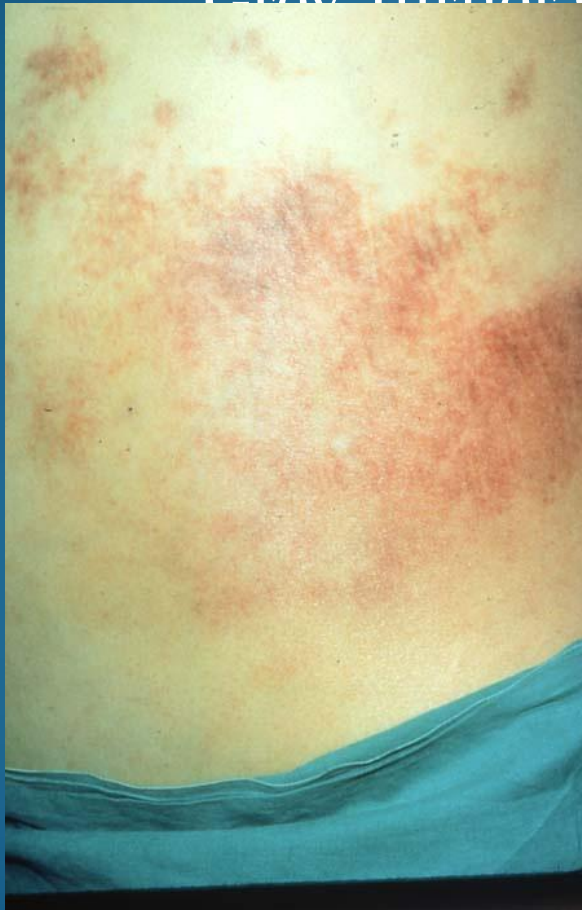**open drainage and respiratory control**

**The patient survived!**



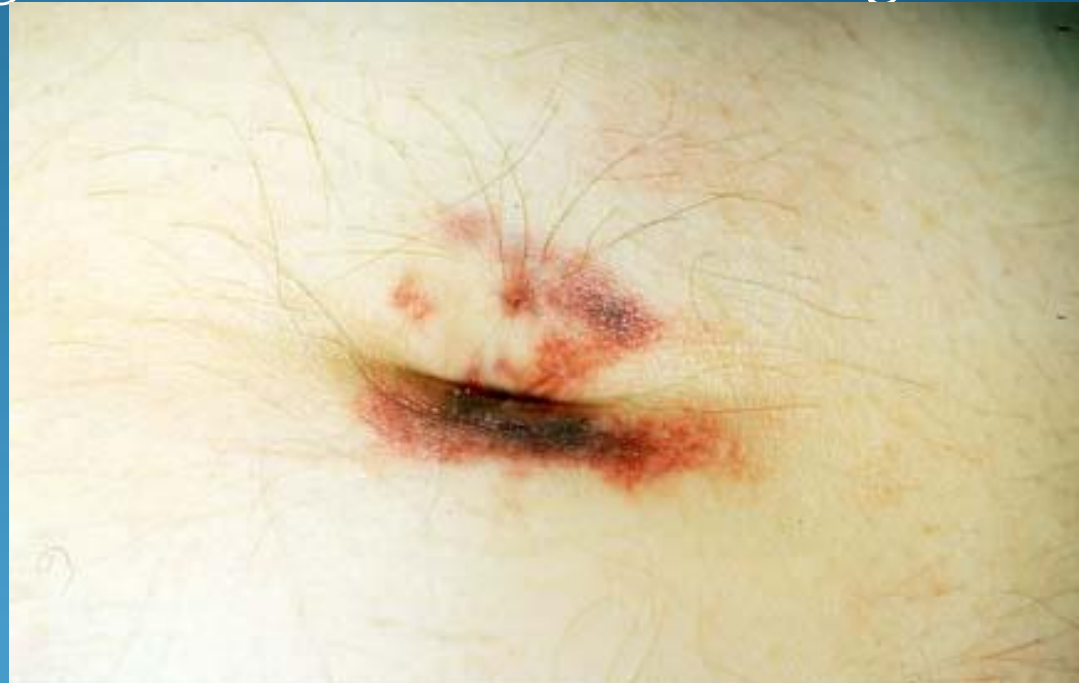

## Grey Turner sign •



Source: Lichtman MA, Shafer MS, Felgar RE, Wang N:  
*Lichtman's Atlas of Hematology*: <http://www.accessmedicine.com>  
Copyright © The McGraw-Hill Companies, Inc. All rights reserved.

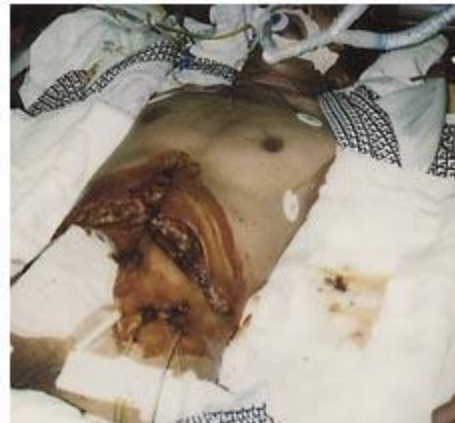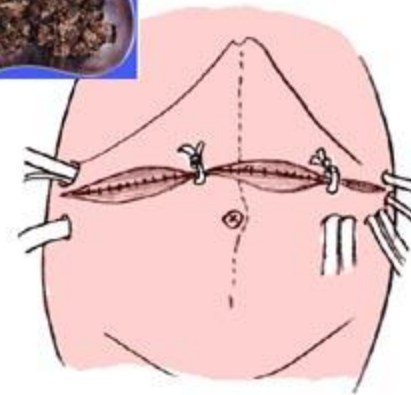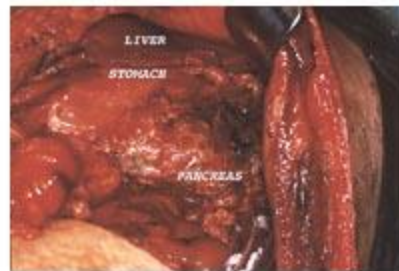
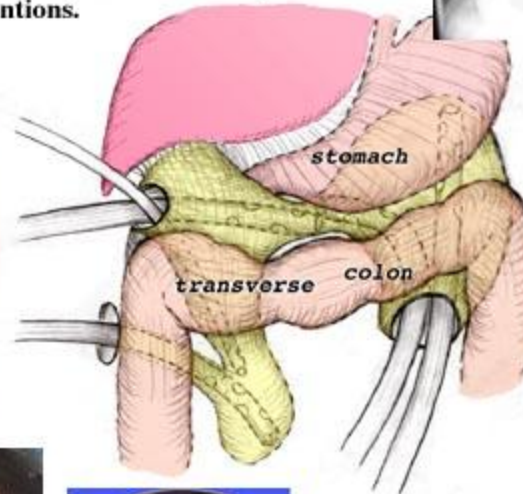
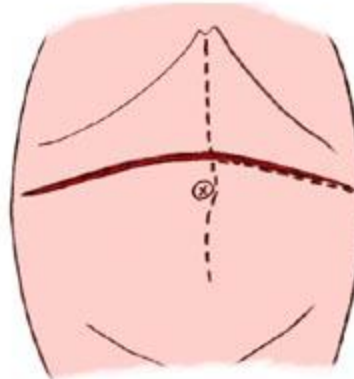
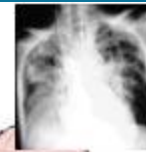## Cullen's sign •



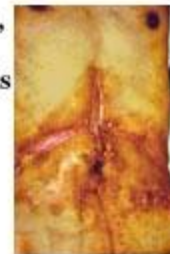Source: Lichtman MA, Shafer MS, Felgar RE, Wang N:  
*Lichtman's Atlas of Hematology*: <http://www.accessmedicine.com>  
Copyright © The McGraw-Hill Companies, Inc. All rights reserved.

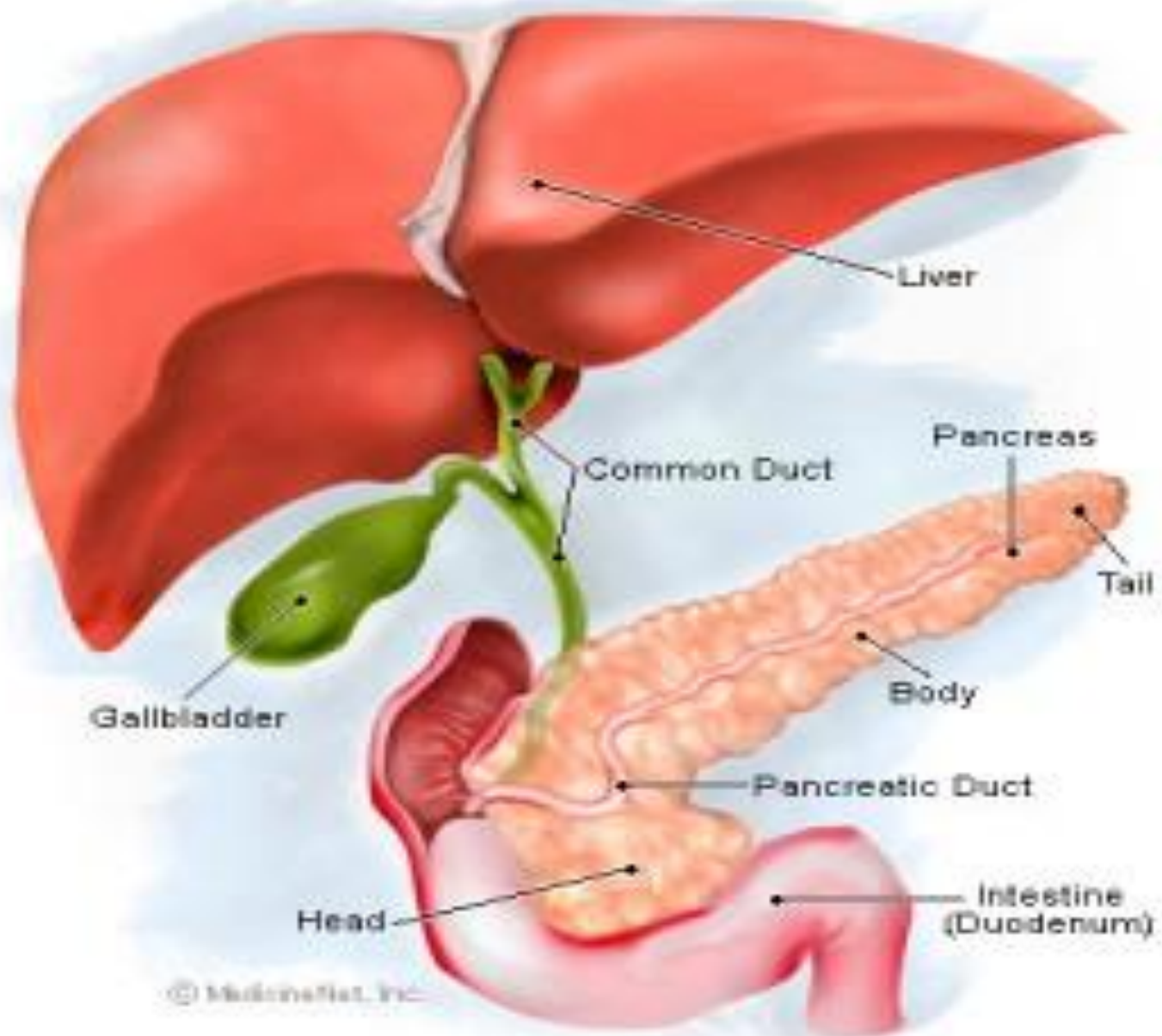
## Surgical procedures for infected peripancreatic necrosis

Infected necrosis associated with generalized complications necessitates surgical interventions.



The transverse incision, even without primary closure, amazingly heals without herniation.





# Physical findings :

The patient is frequently uncomfortable in the supine position and **prefers to sit up or lie on one side** . **midpigastic tenderness** is usually present , and a **mass** may be palpable within the upper abdomen . **Bowel sounds** are quiet or hypoactive , **jaundice** is occasionally present , and signs of **peritonitis** are usually absent , but may occur . the patient may appear **dehydrated** and **hypotensive** , and diffuse **abdominal fullness** or **mild distention** is frequently present .



# Laboratory findings :

Hyperamylasemia

amylase/creatinine clearance ratio

serum lipase levels

elevated white blood cell count

hemoglobin or hematocrit that is either elevated

an increased blood urea nitrogen and creatinine

elevated hepatic enzymes and bilirubin

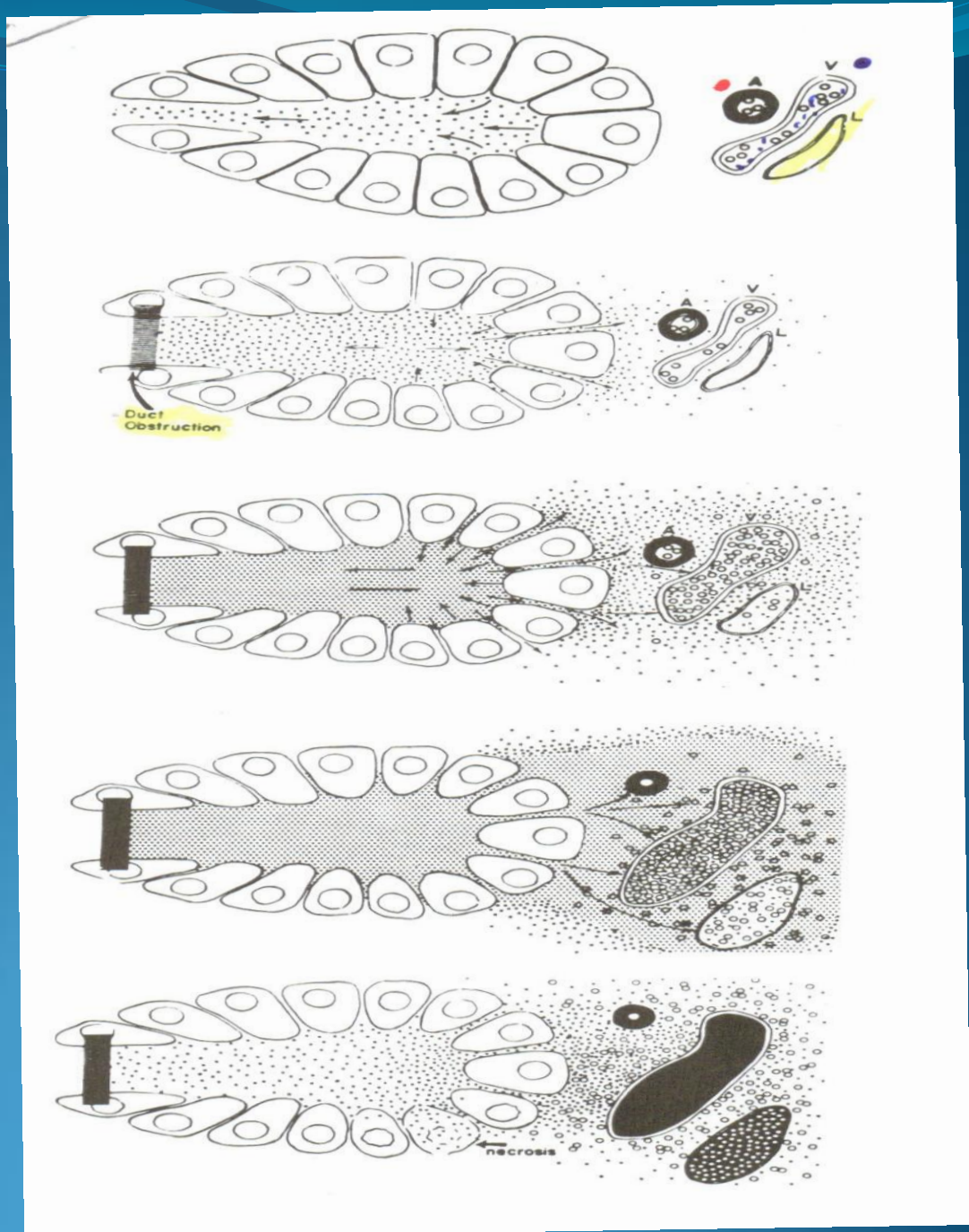
a metabolic acidosis or mixed metabolic and respiratory

acidosis associated with hypoxia

plasma glucose levels may be elevated

plasma calcium may be low

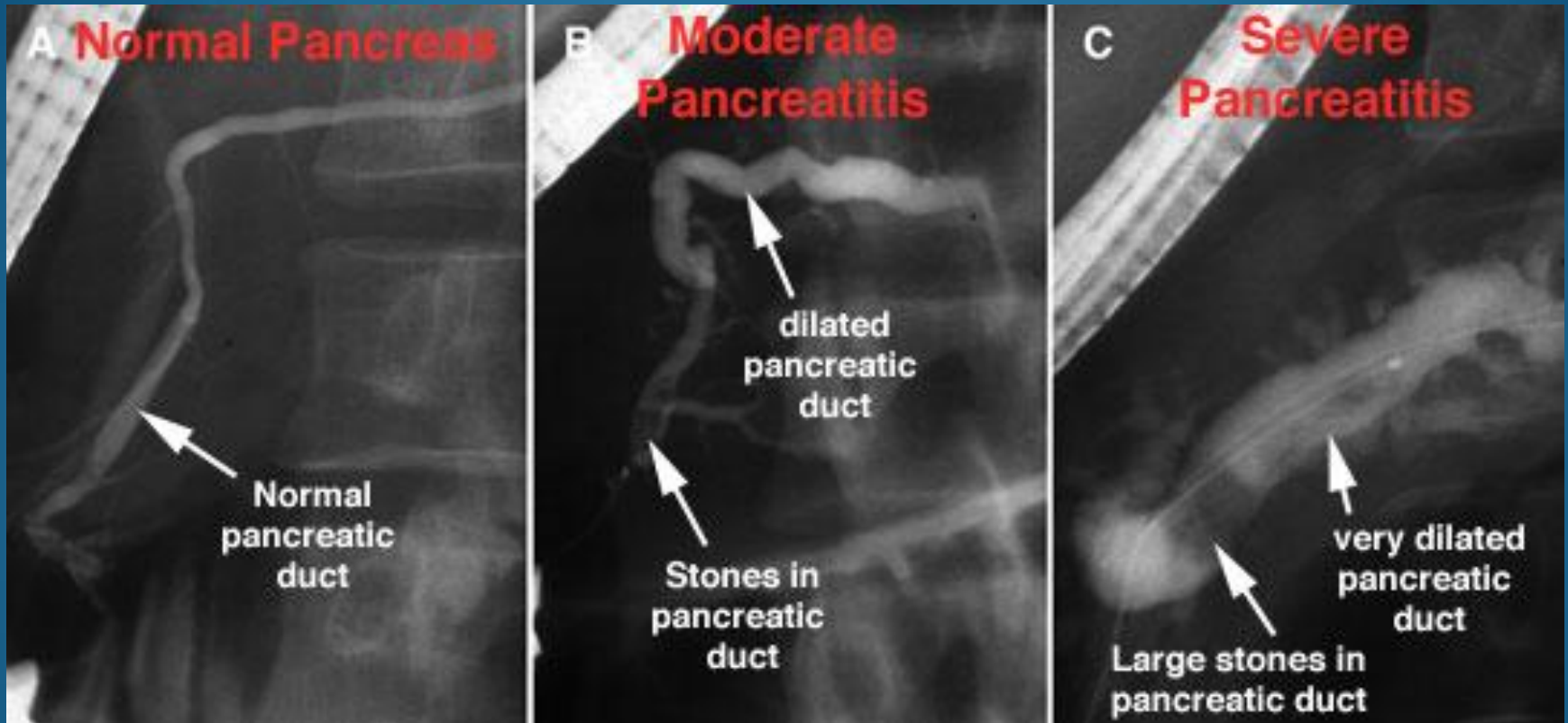
# Schematic representation of the development of severe acute pancreatitis due to obstruction of pancreatic duct



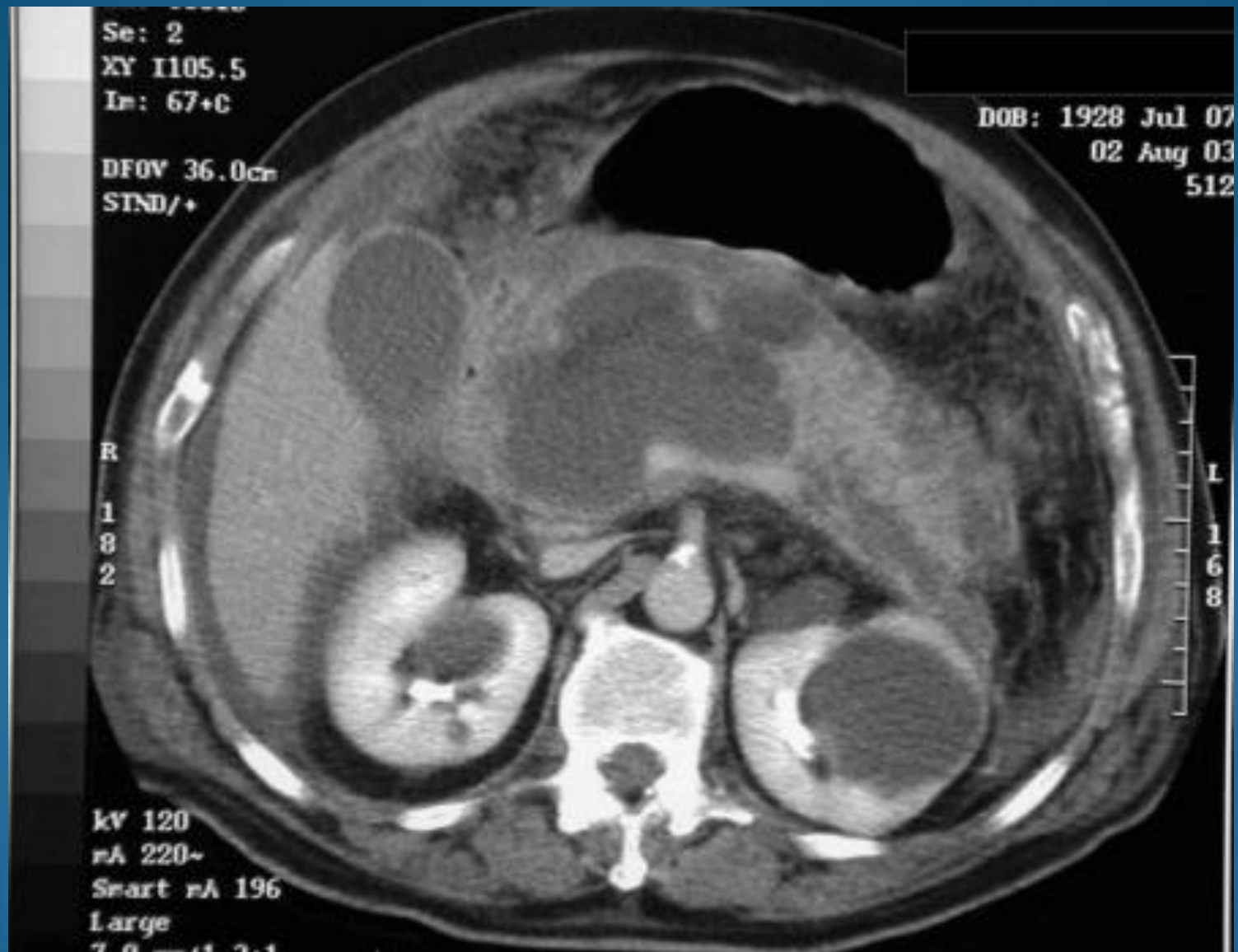
## **Radilogic examinations**

**plain radiography , sonography , and computed tomography (CT) scans of the abdomen may also indicate an enlarged , edematous pancreas, as well as signs of ileus , abscess , or cyst formation .**

# Gall stone pancreatitis by ERCP

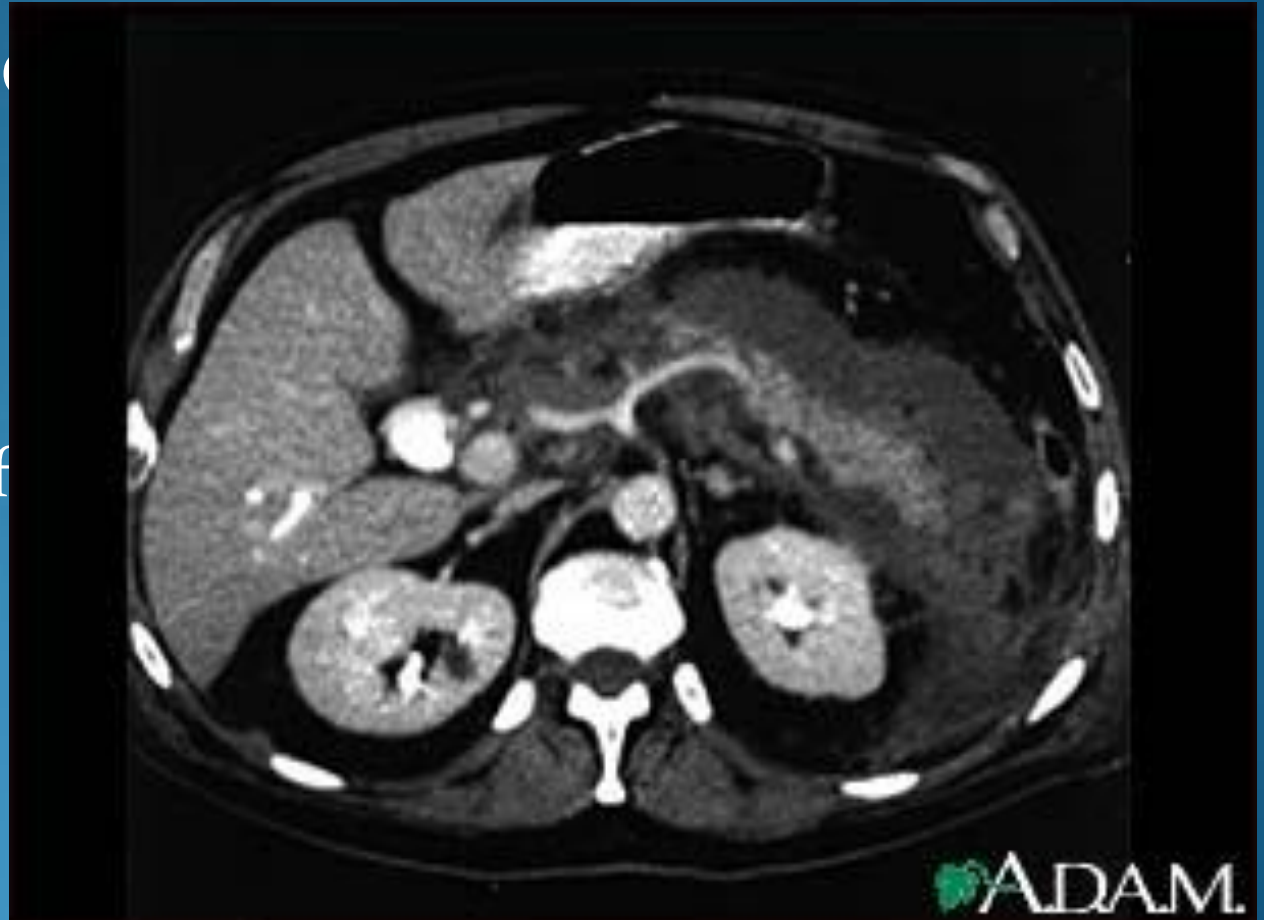




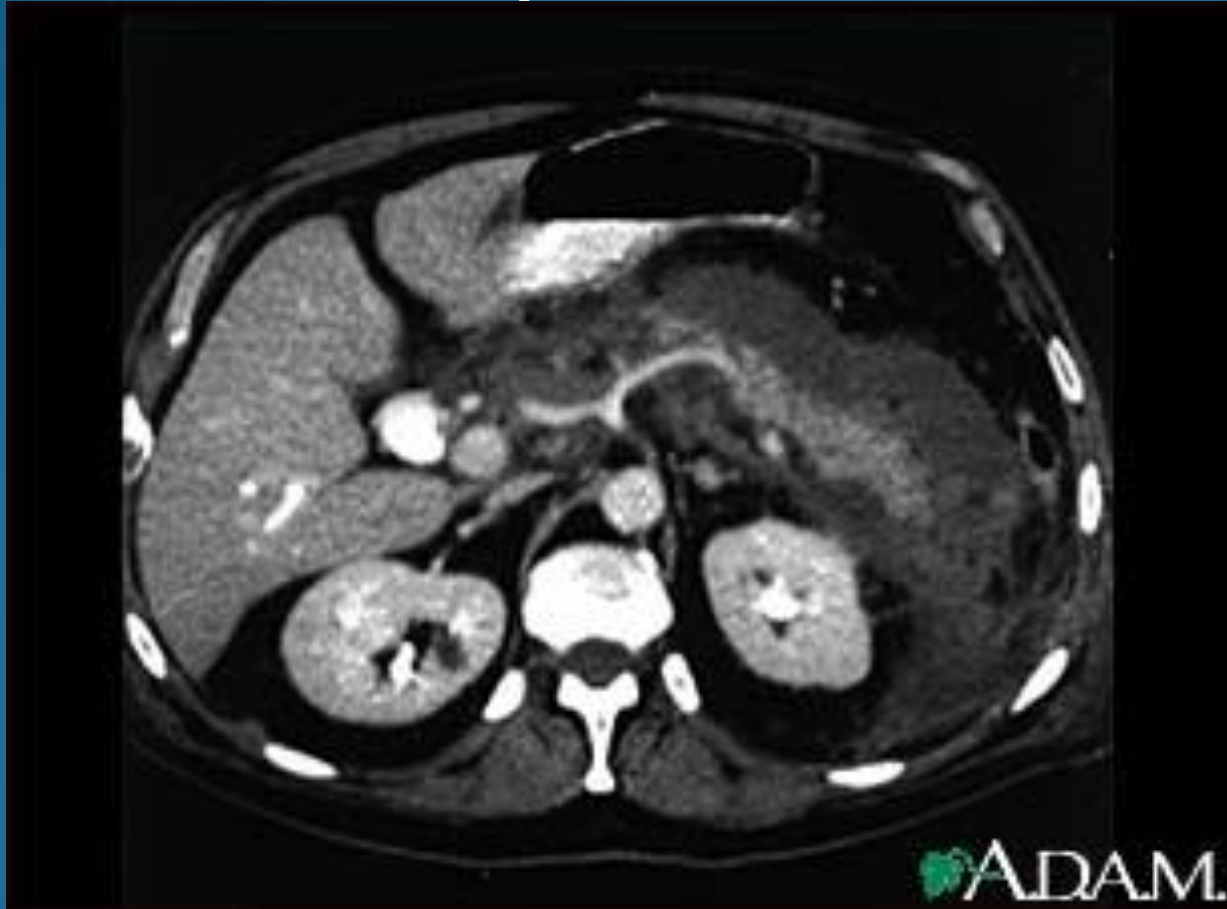
# CT Scan of acute pancreatitis

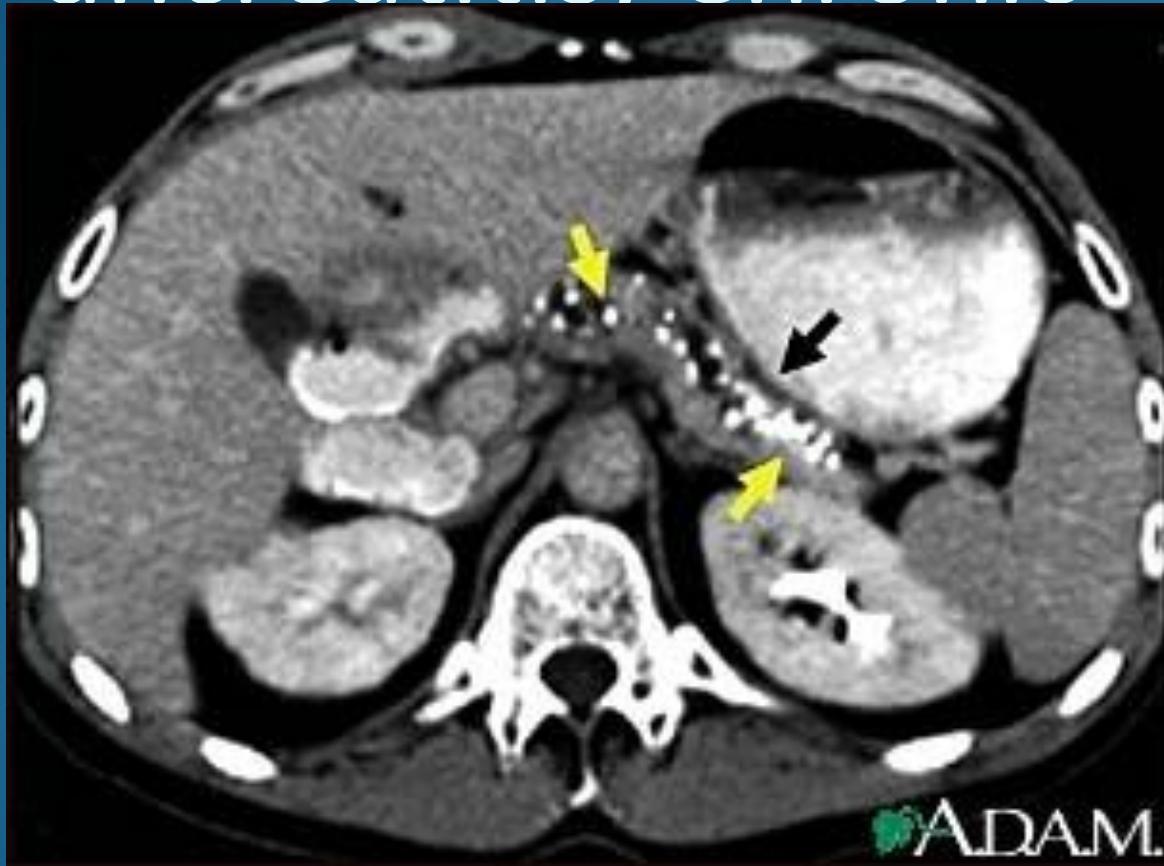inf



# Pancreatitis, Acute - CT Scan

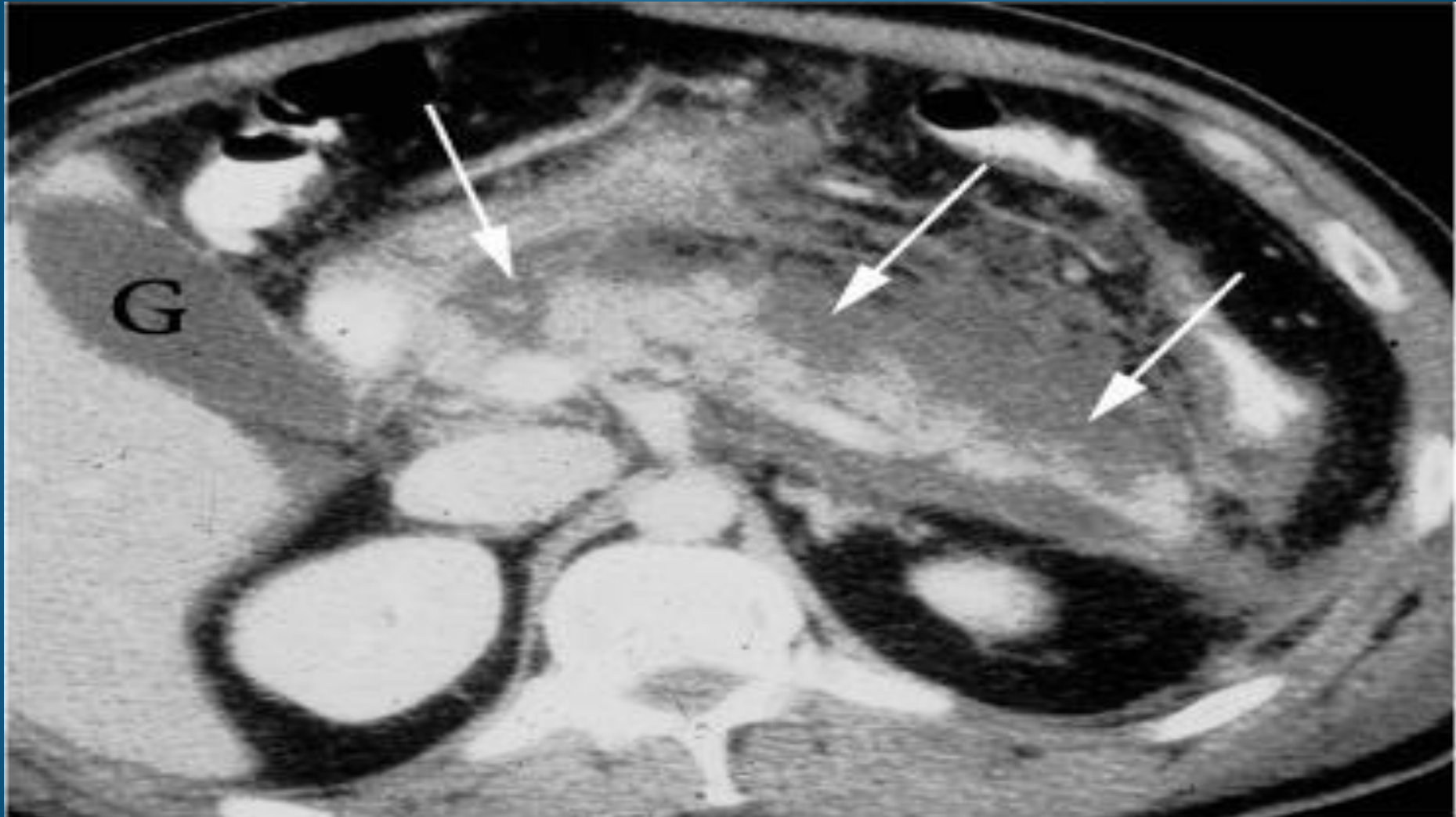


# Pancreatitis, Chronic - CT Scan

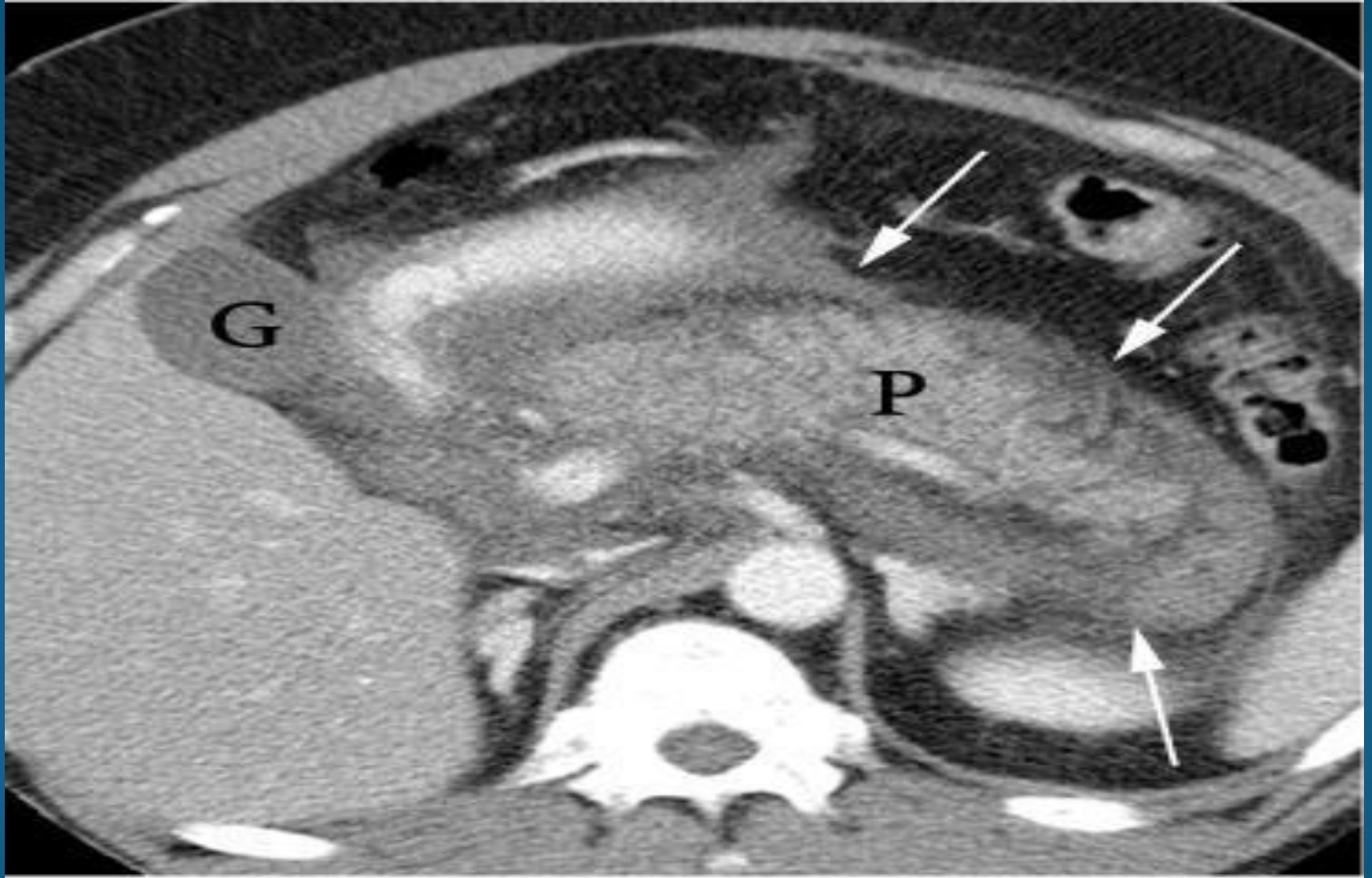




# Necrotizing pancreatitis



# Interstitial pancreatitis



# Clinical course and complications

Pathologic changes in acute pancreatitis range from interstitial edema with mild inflammatory cell infiltrates to necrosis of acinar elements , focal hemorrhage and massive edema , to extensive coagulation necrosis of whole areas of the gland with necrosis of peripancreatic tissues and blood vessels causing massive retroperitoneal hemorrhage

# Clinical course and complications

the most common cause of morbidity and mortality is sepsis

abscess and pseudocyst formation and the development of pancreatic fluid extravasation

adjacent structures including the stomach, duodenum, and biliary ducts may become involved in regional edema and necrosis, causing obstruction or local hemorrhage

splenic or portal vein thrombosis may occur and may cause variceal hemorrhage with preexisting portal hypertension



# Clinical course and complications

pulmonary insufficiency

Pneumonia

ARDS

Oliguria

Azotemia

renal vessel thrombosis may cause renal failure

DIC

pericardial effusion

# Treatment :

## Supportive therapy :

the patient is given **nothing by mouth** , and a **nasogastric tube** is strongly recommended.

**Analgesics**

**Antibiotics**

**intravenous fluid administration**

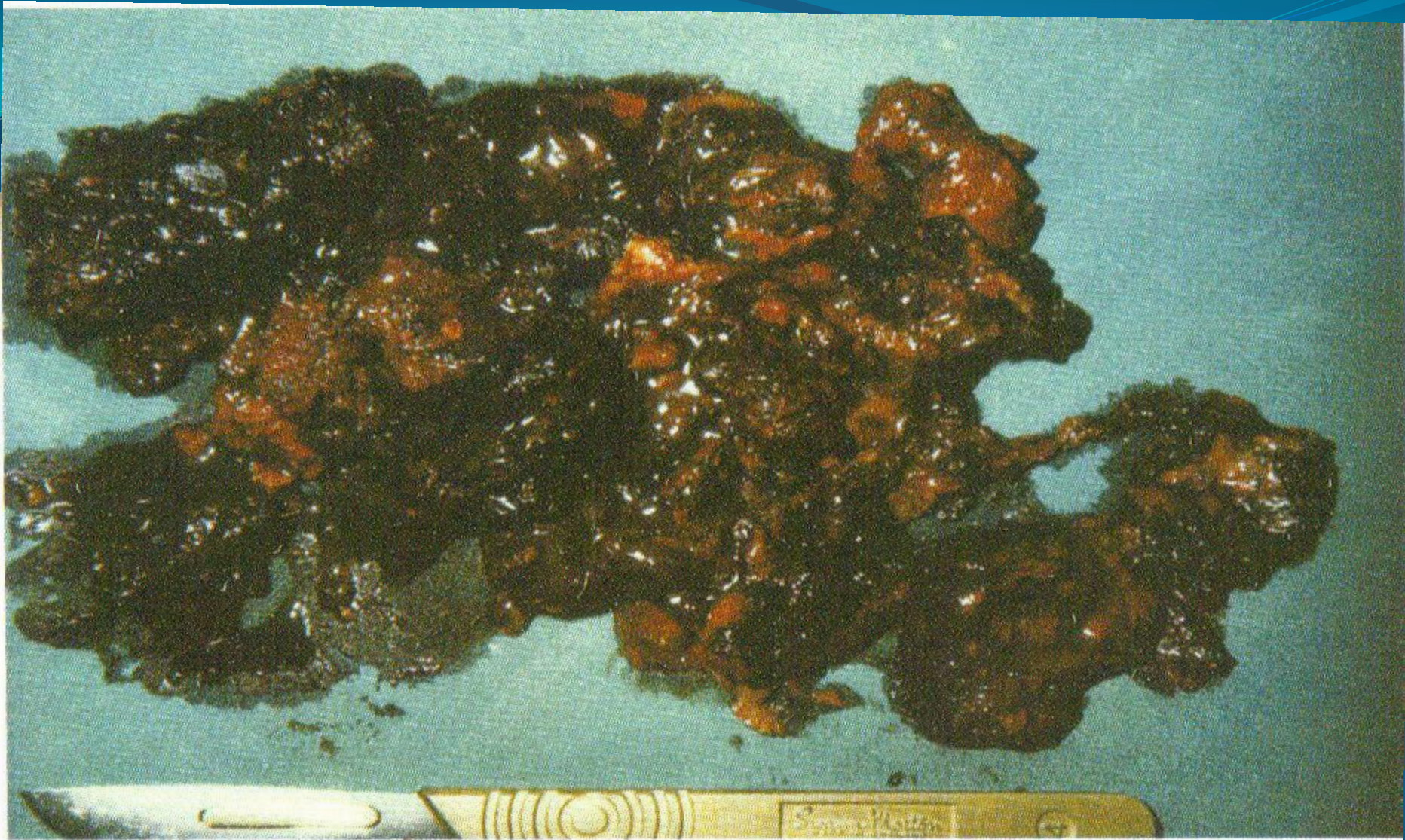**nutritional support (parenteral)**

**monitoring of blood glucose levels**

**ventilatory support (if needed)**

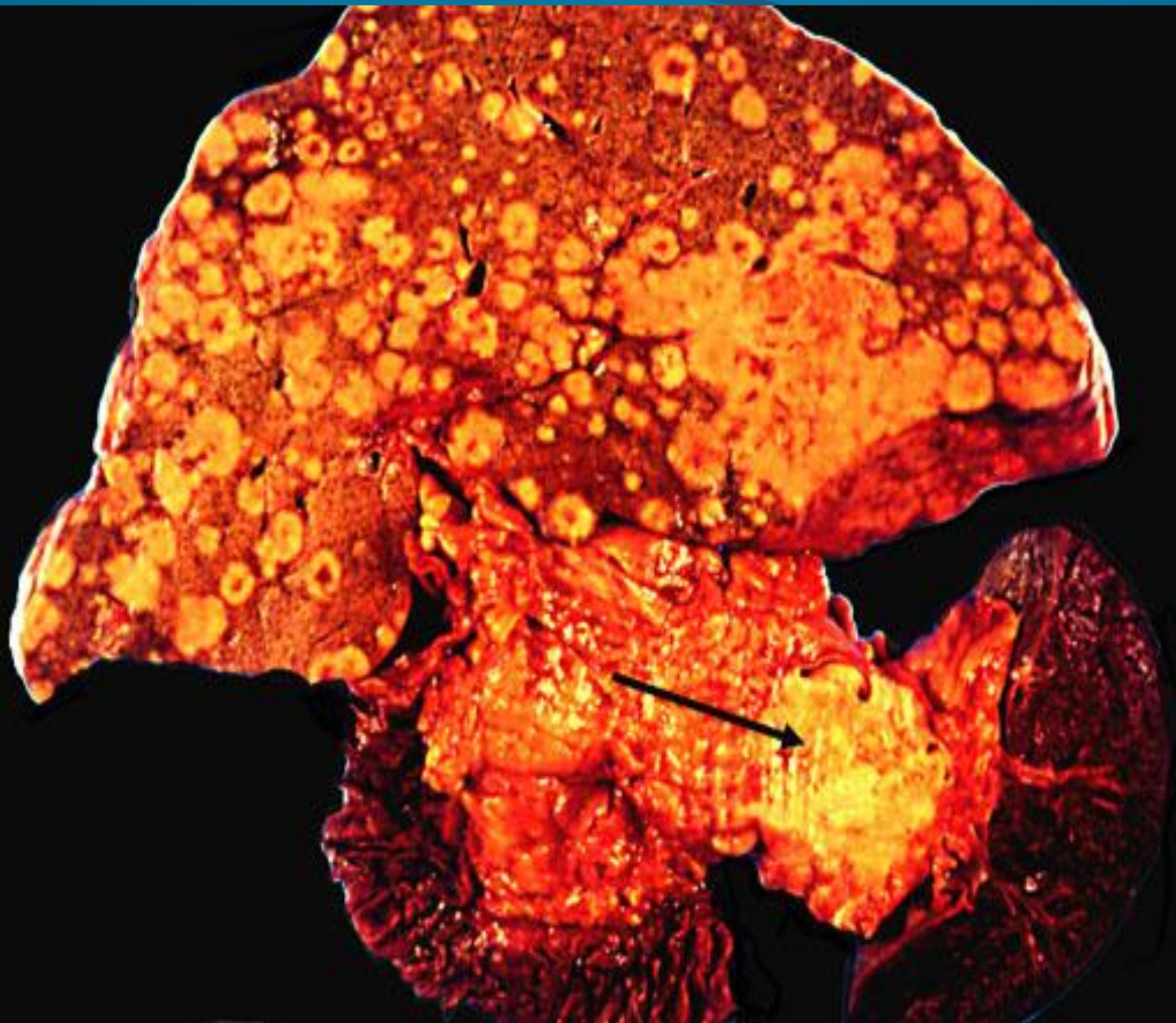
**peritoneal lavage**





**Figure 24.2** Operative specimen following necrosectomy for acute necrotizing pancreatitis.







# Treatment :

## Surgical intervention :

extensive lavage and sump drainage of the region of the pancreas improves survival and should be considered if retroperitoneal necrosis is present .

resection or debridement of the necrotic gland with extensive open drainage of the region  
operative therapy may be required in acute pancreatitis associated with biliary calculus disease .

# Chronic pancreatitis

## Etiology and pathophysiology :

alcohol abuse

chronic inflammation and fibrosis may be caused by: trauma, biliary tract disease , or hypercalcemia

Laennec's cirrhosis

# Chronic pancreatitis

## Clinical presentation and diagnosis :

**persistent abdominal pain:**

**steady , and it may be exacerbated by eating or may occur as separate crises of pain associated with bouts of heavy alcohol ingestion .**

**nausea and vomiting**

**less hemodynamic instability**

# Chronic pancreatitis

abdominal examination : usually reveals **moderate tenderness** in the midepigastrium , and upper abdominal , **fullness** or a palpable **mass** may be present .

a history consistent with **steatorrhea** may be present

unremarkable **bowel function**



# Chronic pancreatitis

## laboratory studies:

normal or only modestly elevated serum

amylase levels

white blood cell counts . hyperglycemia is common

low-grade elevations of bilirubin and alkaline phosphatase

liver enzyme elevations

parameters of malnutrition

# Chronic pancreatitis

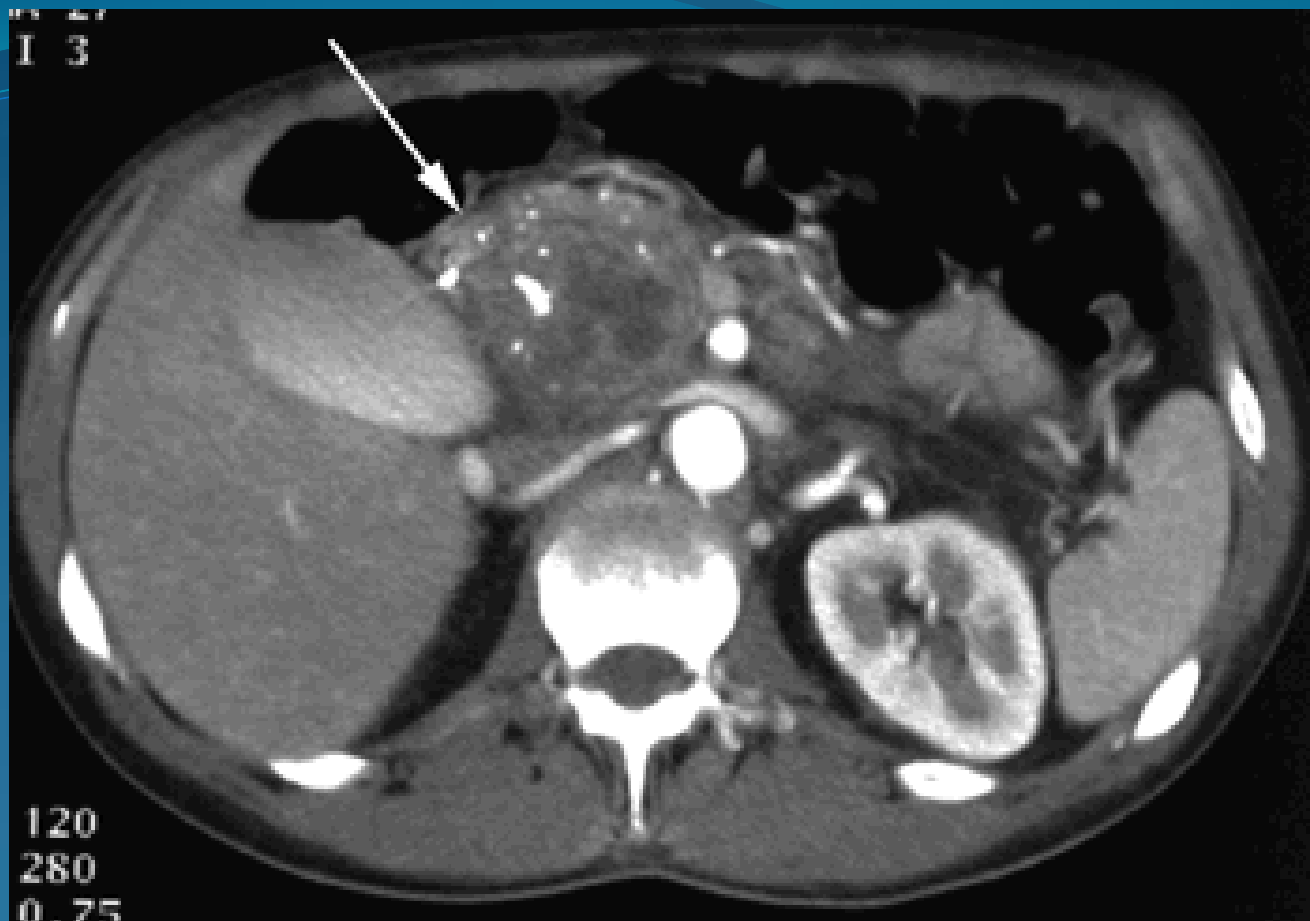## radiologic studies :

plain radiographs of the abdomen

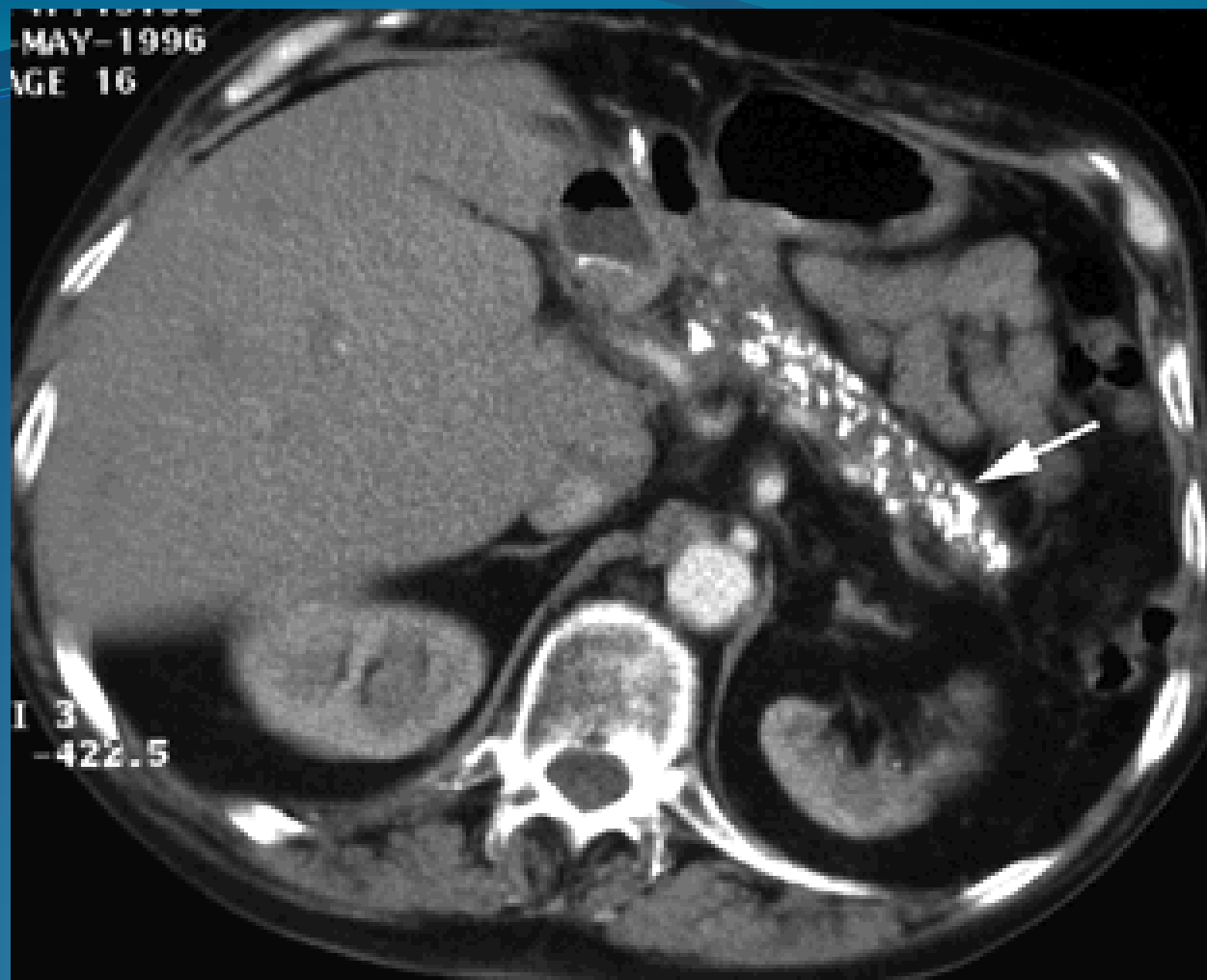
sonograms and CT scans

ERCP

functional tests of exocrine function or  
endocrine function

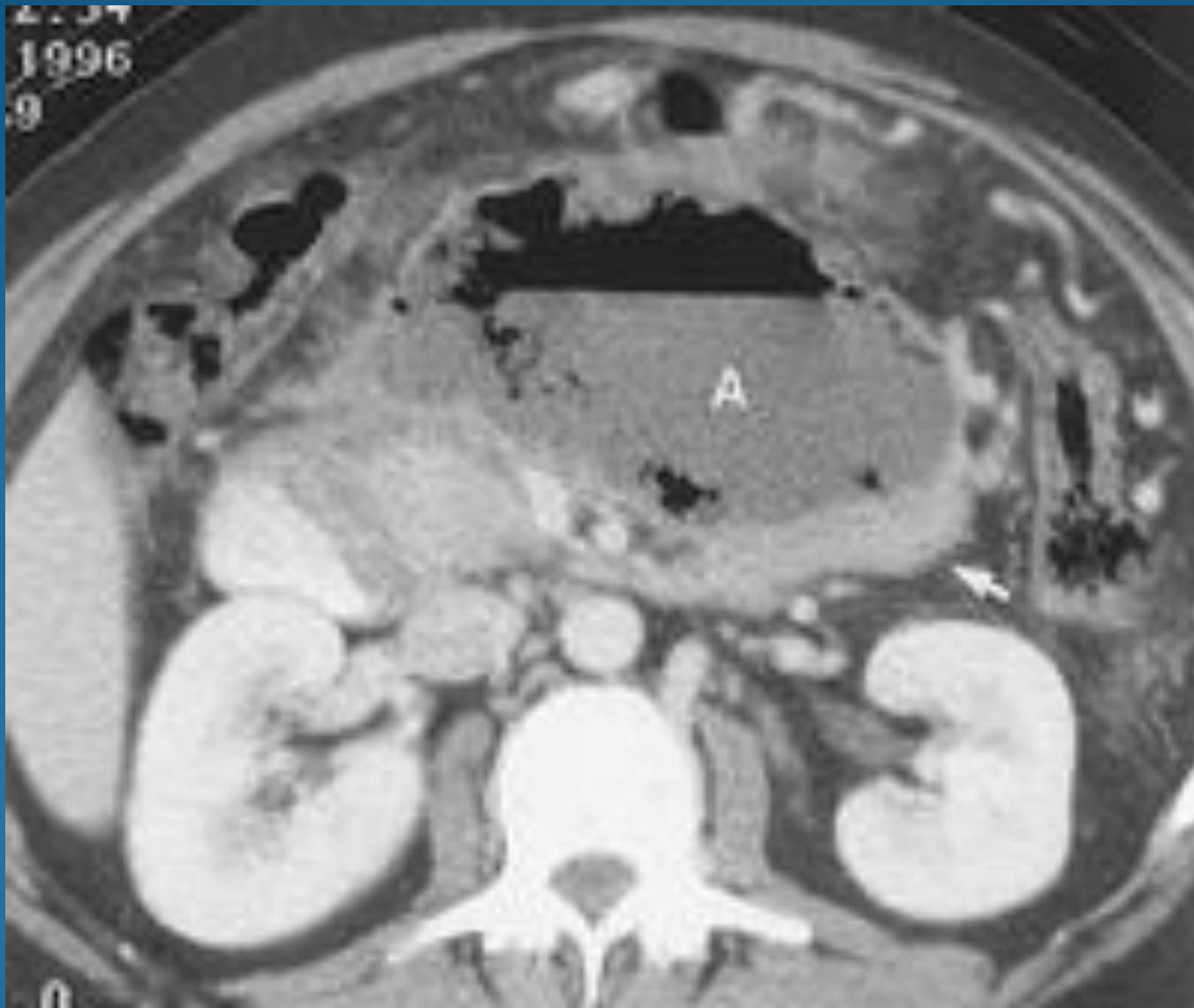

**Acute pancreatitis superimposed upon chronic pancreatitis** CT scan through the upper abdomen in a patient with chronic pancreatitis demonstrates a large complex inflammatory mass in the head of the pancreas (arrow) with calcifications (indicative of chronic disease) and low attenuation areas of necrosis. Courtesy of Jonathan Kruskal, MD.

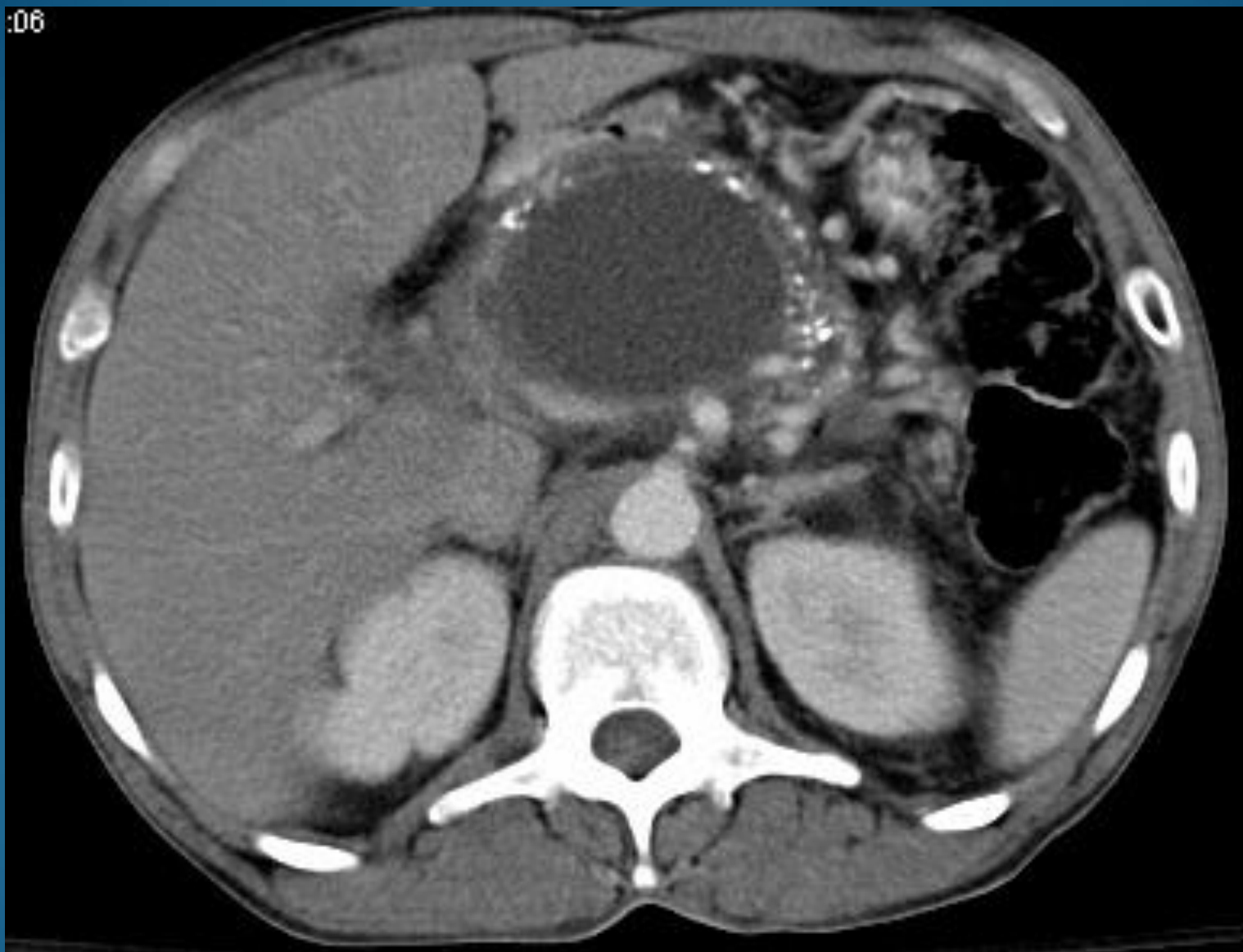


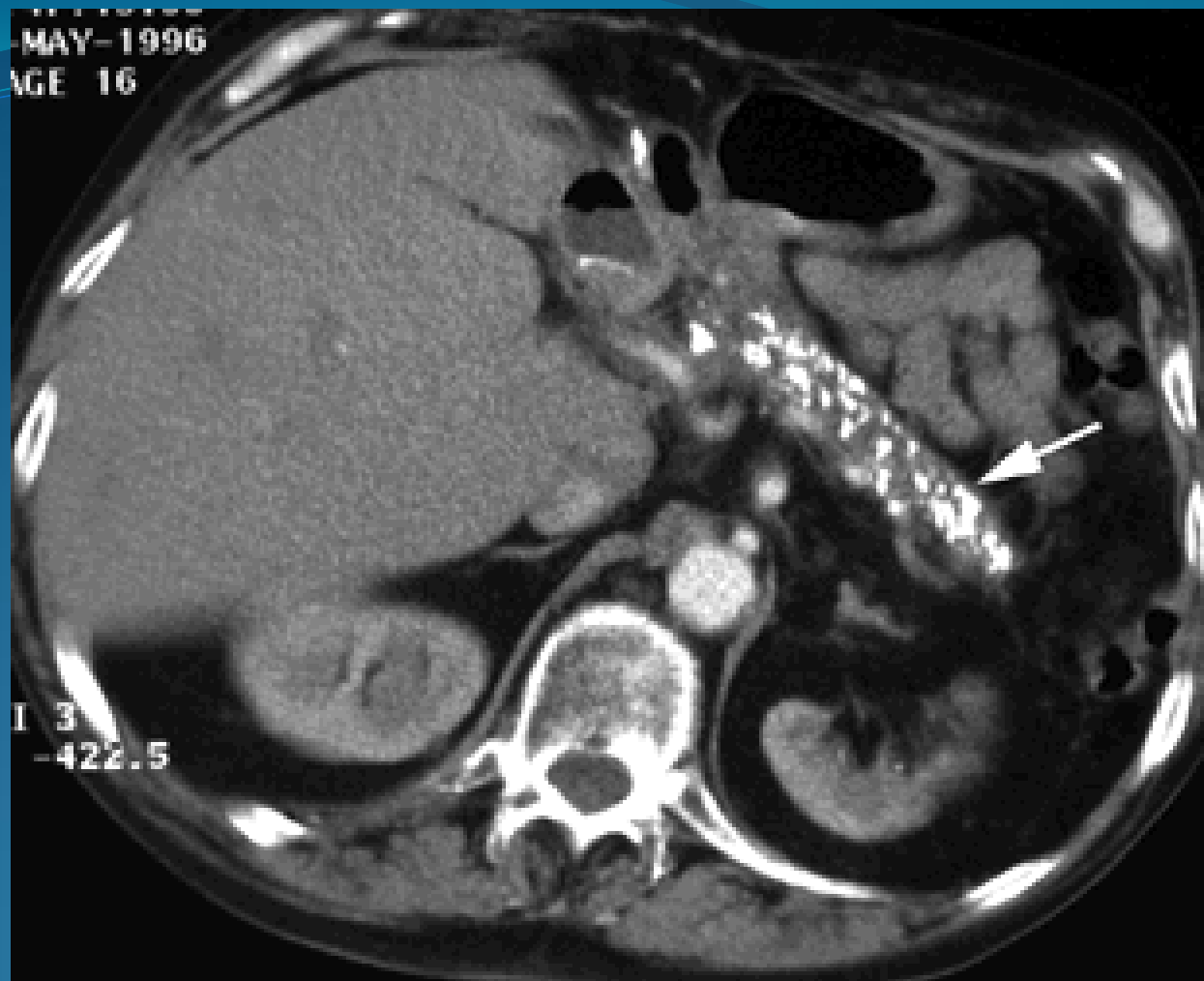
**Chronic pancreatitis** CT scan of a patient with chronic pancreatitis demonstrates coarse calcifications (arrow) distributed throughout the body and tail of the pancreas. Courtesy of Jonathan Kruskal, MD.





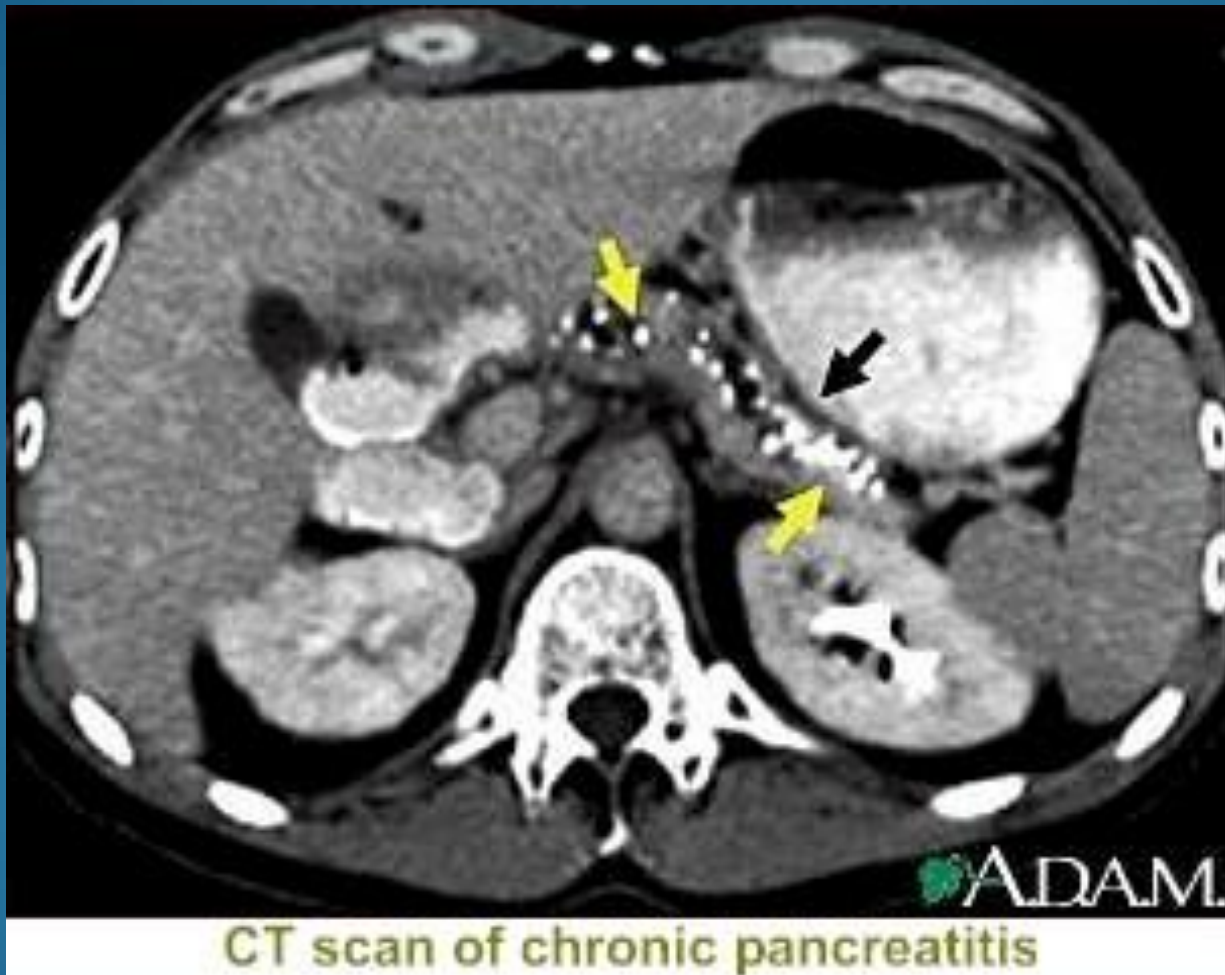
:06





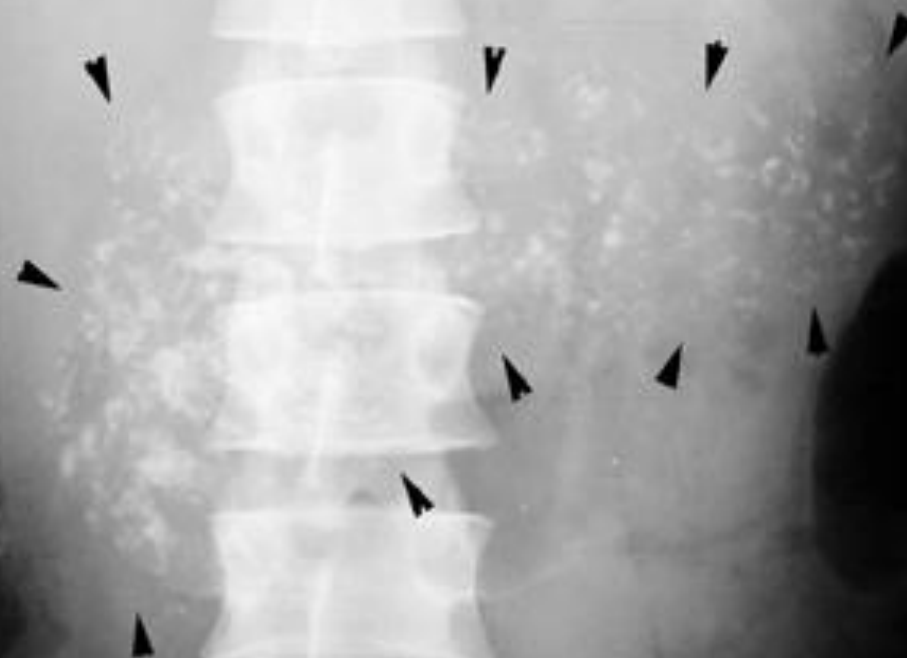**Chronic pancreatitis** CT scan of a patient with chronic pancreatitis demonstrates coarse calcifications (arrow) distributed throughout the body and tail of the pancreas. Courtesy of Jonathan Kruskal, MD.

# CT - chronic pancreatitis

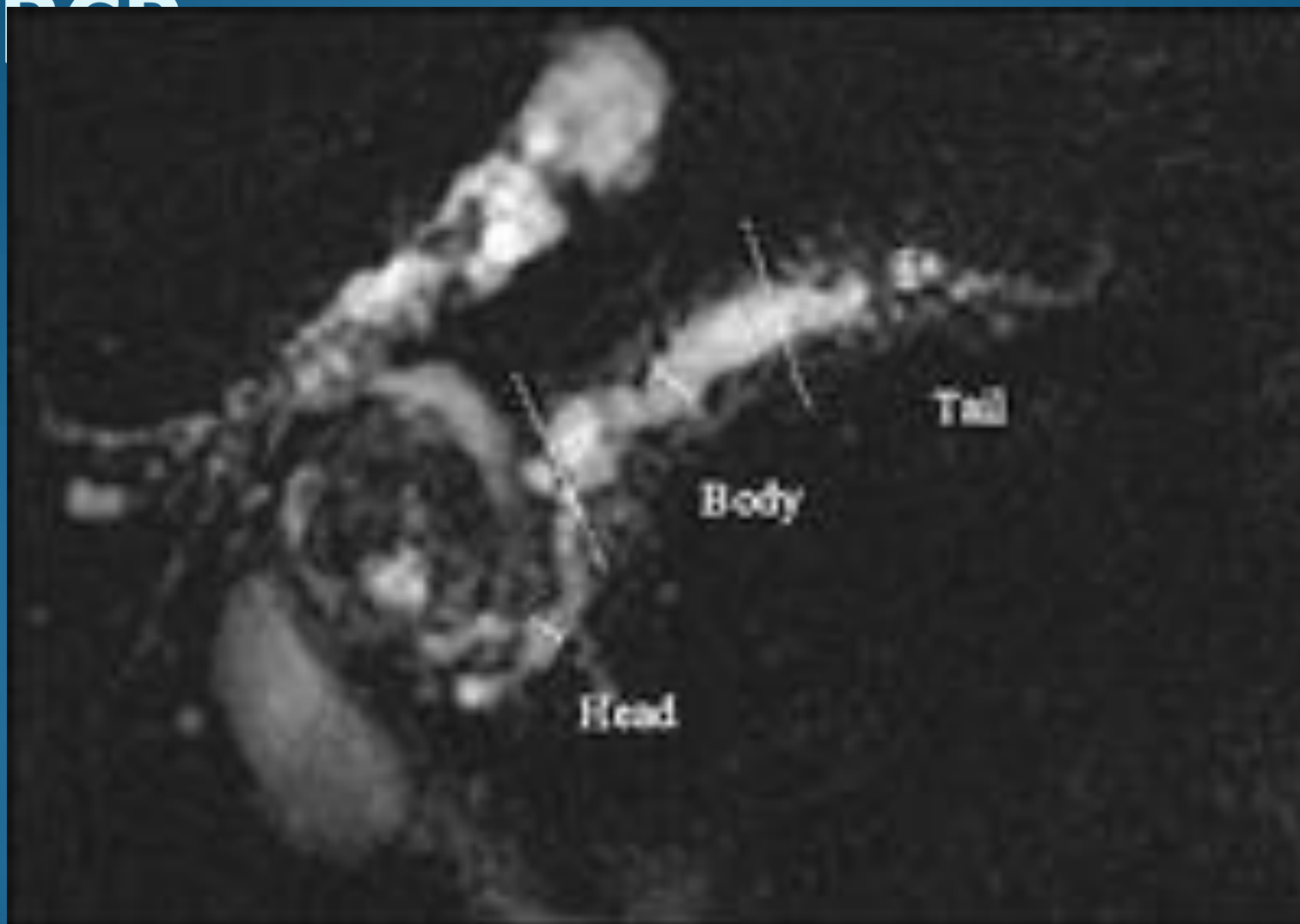

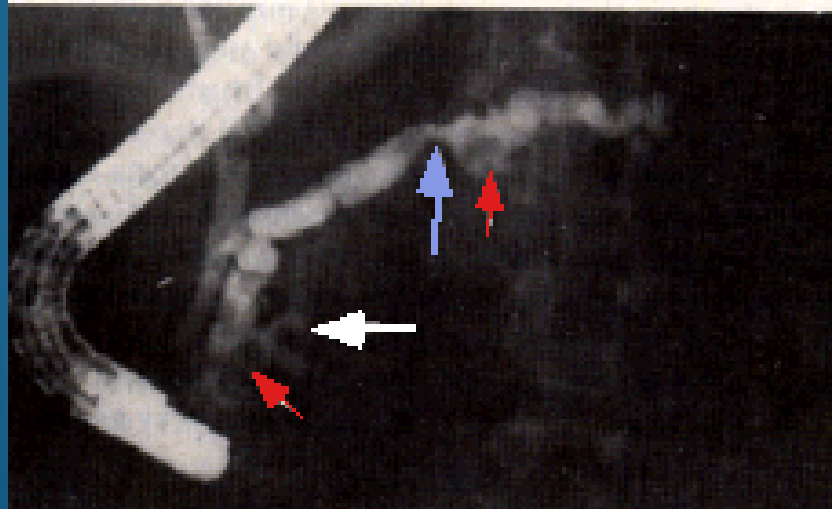
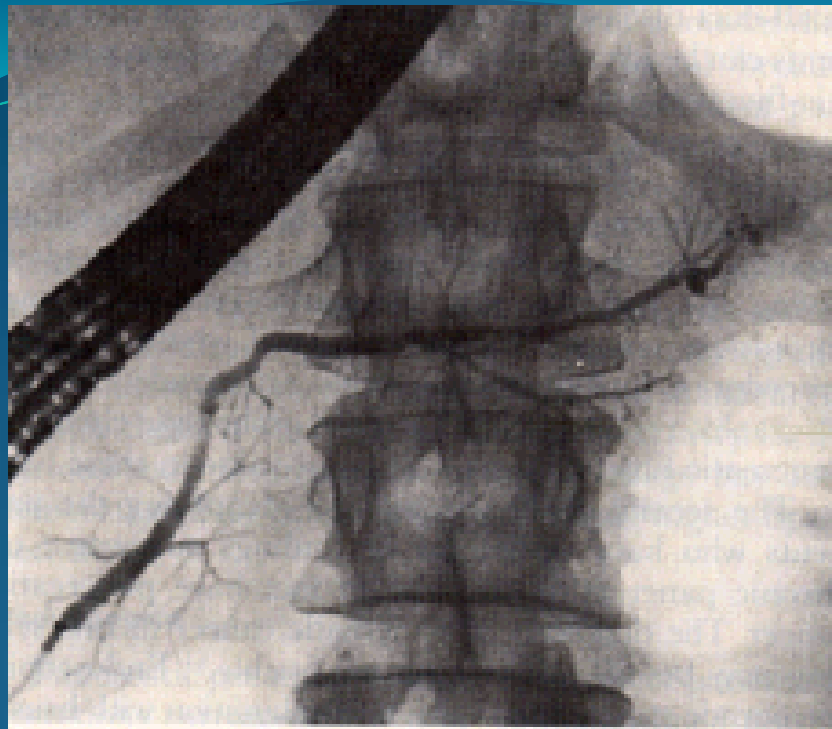


EXTENSIVE PANCREATIC  
CALCIFICATION



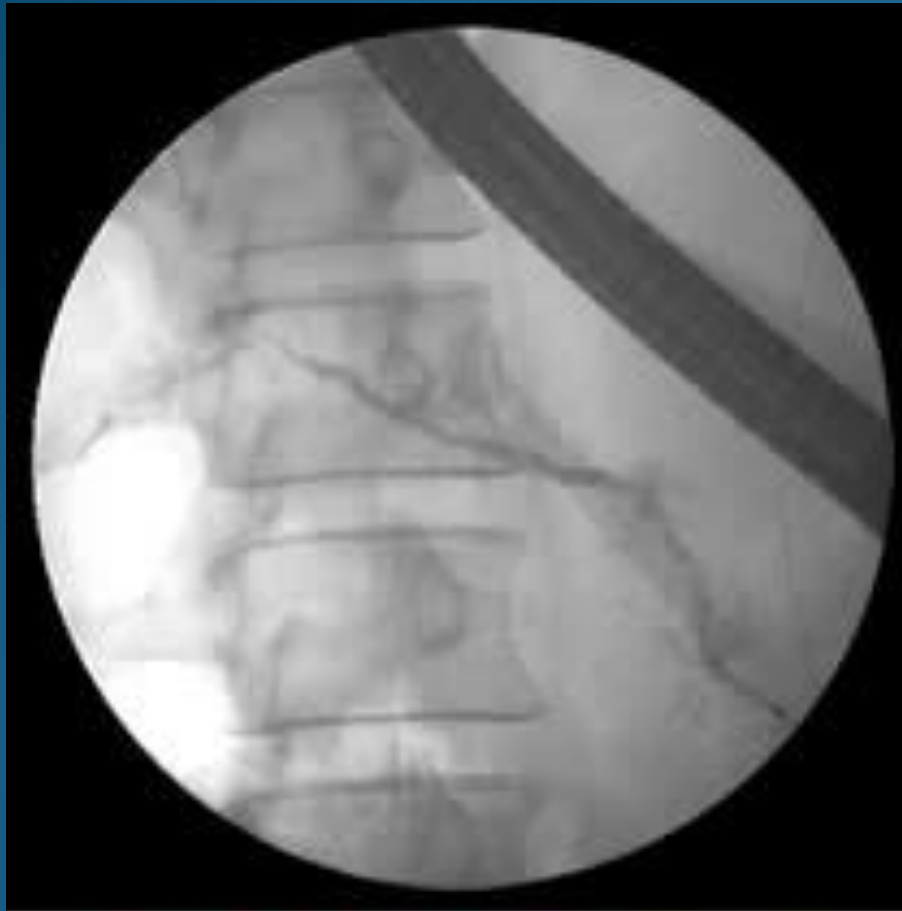
# MRCP



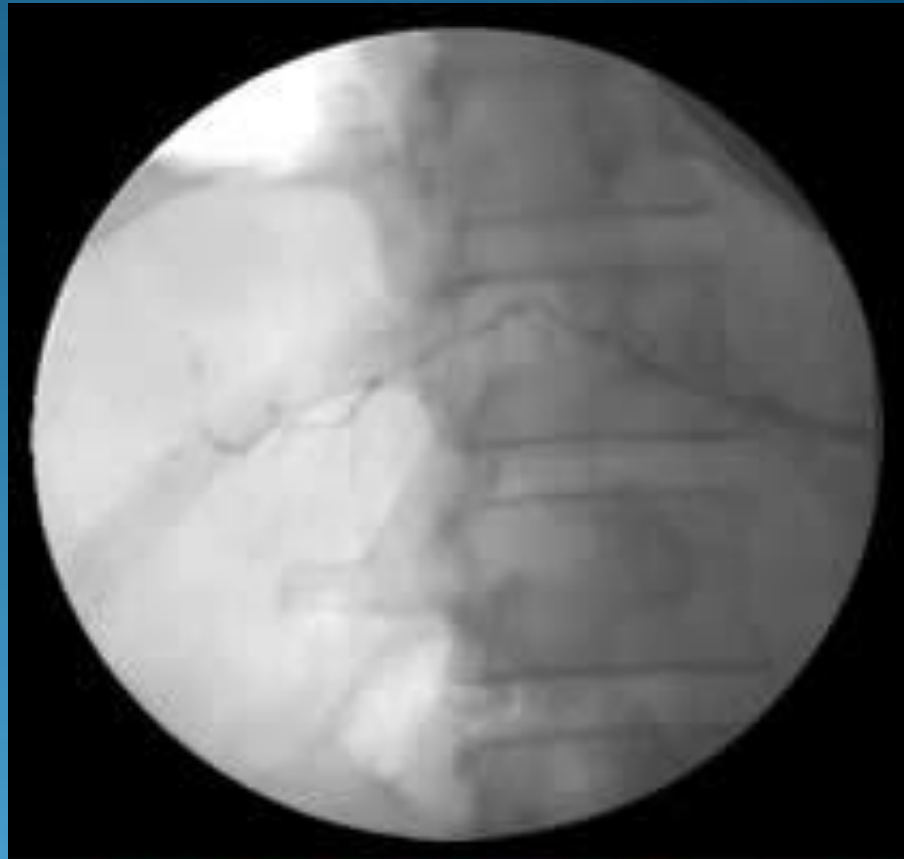

## ERCP in chronic pancreatitis

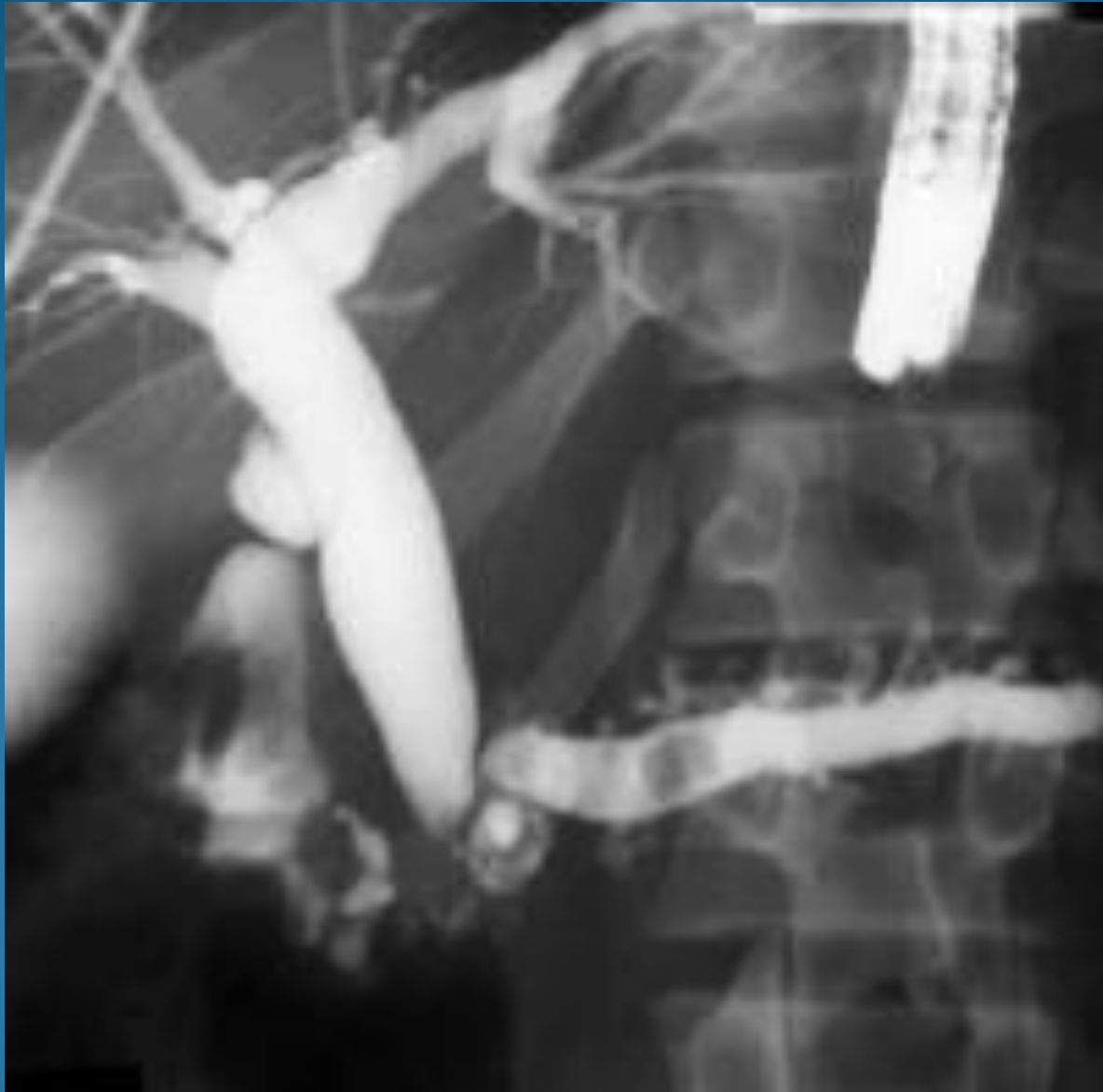Top panel: Normal subtraction endoscopic retrograde pancreatogram shows the filling of normal side branches and a smooth, nondilated main ductal system. Bottom panel: Endoscopic retrograde pancreatogram in a patient with chronic pancreatitis, revealing a dilated, tortuous main duct that contains stones or protein plugs (lucencies in duct marked by short red arrows). A stricture is visible in the midportion of the duct (blue arrow) and there is dilation of the uncinus-process branch (white arrow). (With permission from Steer, ML, Waxman, I, Freedman, SD, N Engl J Med 1995; 332:1482.)



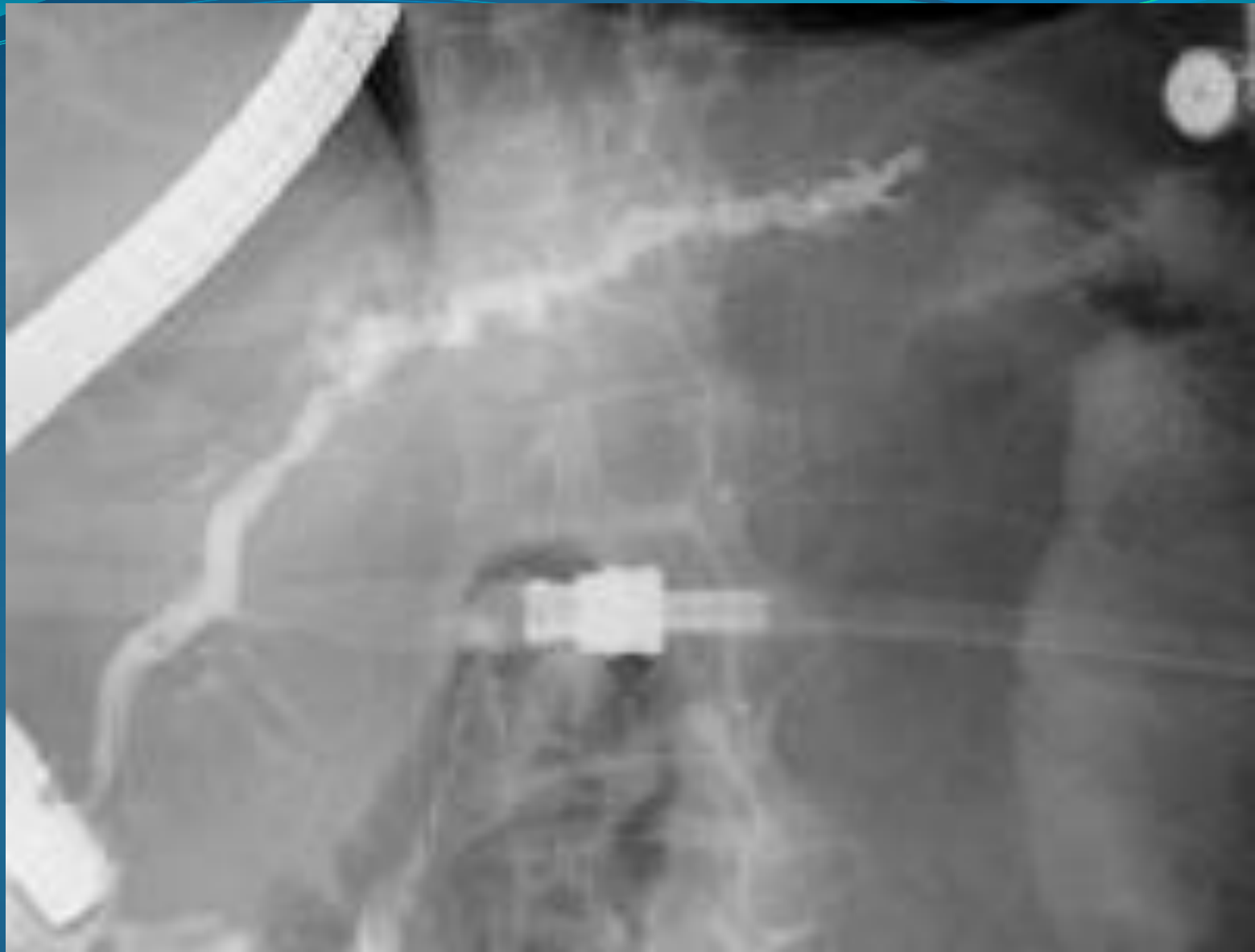**Image 5.** ERCP showing irregular pancreatic duct.



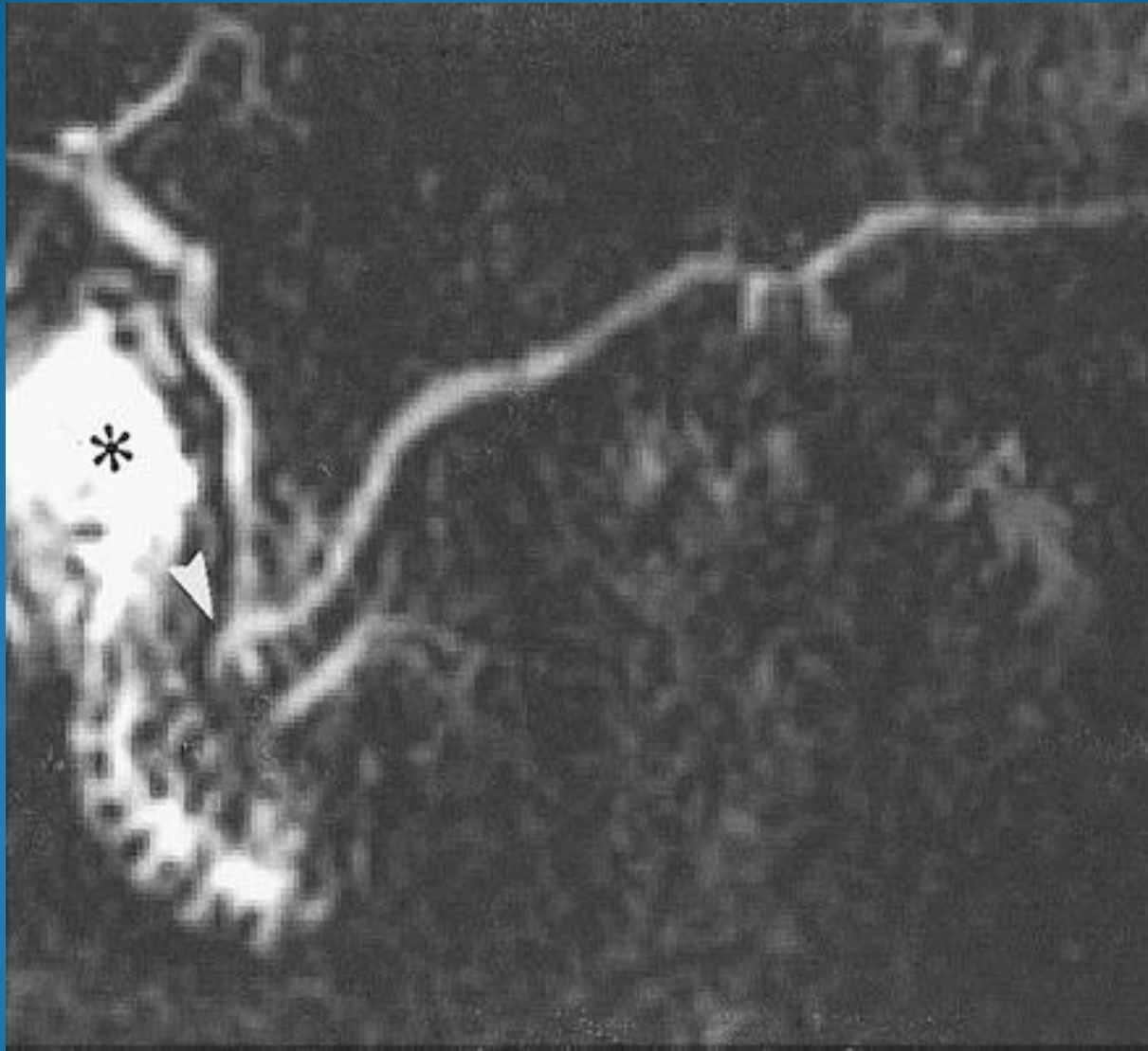
**Image 6.** ERCP showing irregular tail of pancreatic duct.



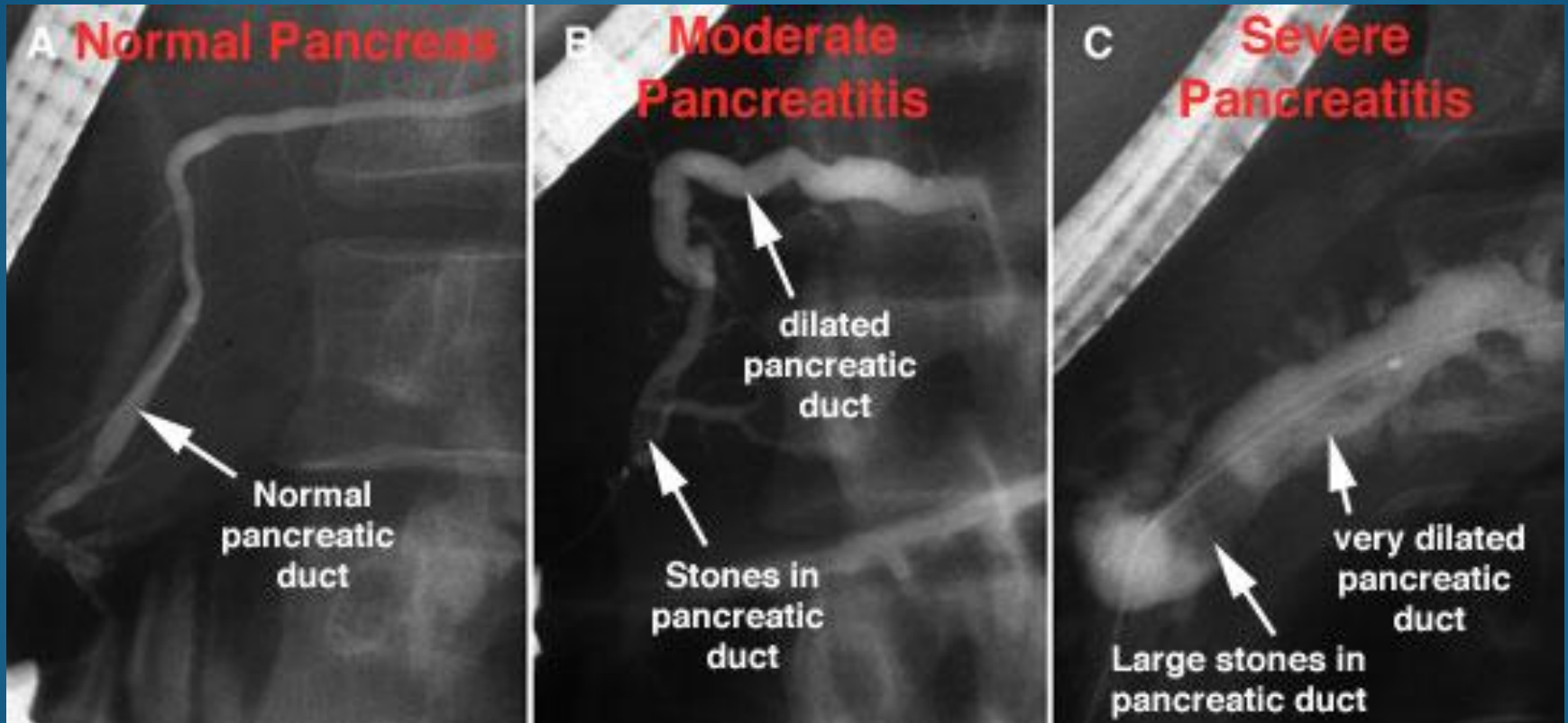


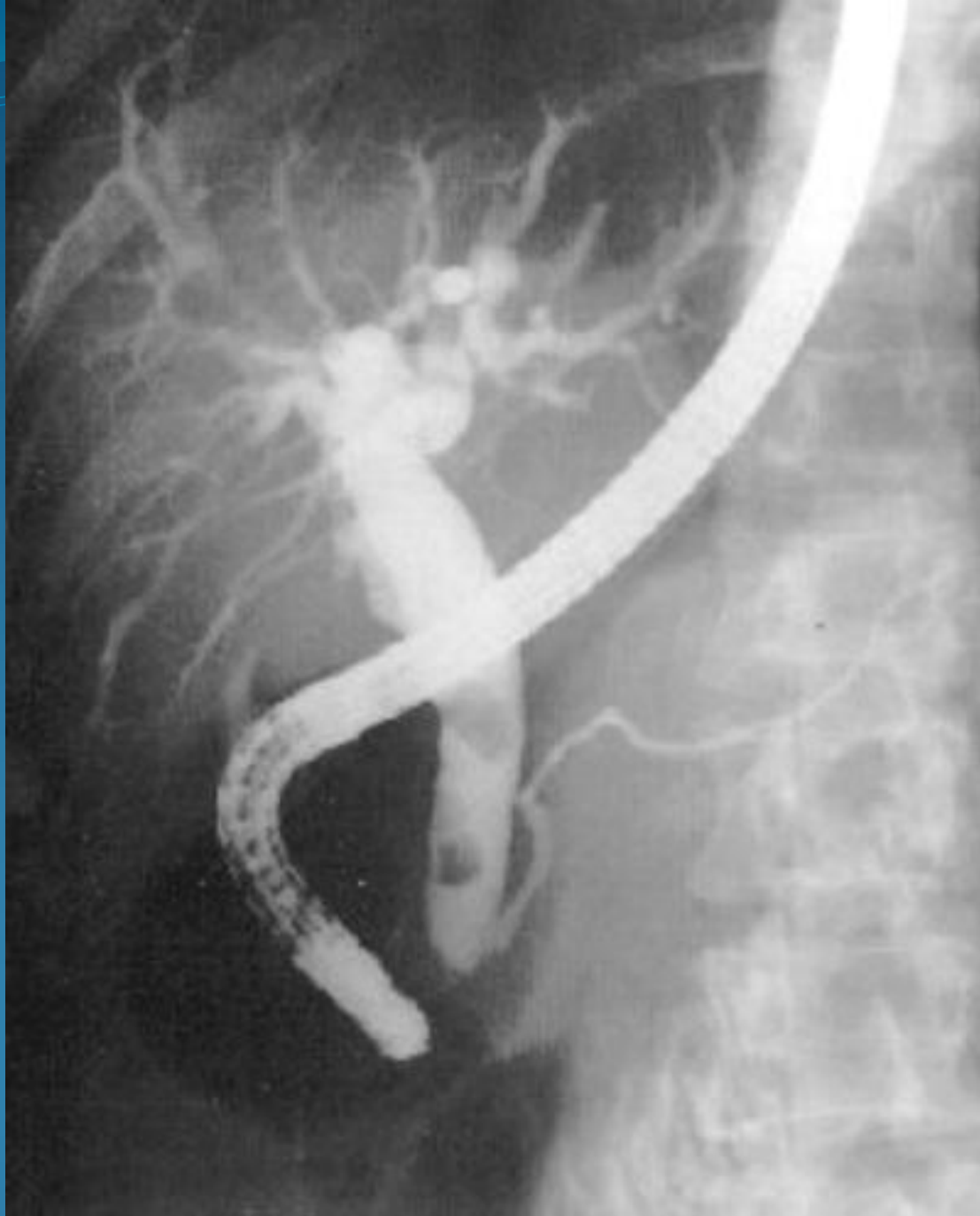

# MRCP of pancreas divisum



# Gall stone pancreatitis by ERCP







# Chronic pancreatitis

## Clinical course and complications :

persistent **pain** associated with progressive signs and symptoms of exocrine and endocrine insufficiency . acute exacerbations of severe pain are associated with duct obstruction and cyst formation .

progressive **malnutrition** and **general debilitation** and frequently exhibit heavy dependence on analgesics

# Chronic pancreatitis

## Clinical course and complications :

splanchnic and gastrointestinal complications include biliary tract disease (with calculus formation or common duct stenosis) , portal hypertension , splenic vein thrombosis , gastritis , duodenitis , as well as complications of pseudocyst disease

Sepsis

# Chronic pancreatitis

## Treatment :

### Supportive therapy :

the removal of precipitating factors such as alcohol , drugs , or hypercalcemia , with appropriate treatment of pain , steatorrhea , weight loss , and diabetes .

control the exocrine and endocrine deficiency

### Surgical therapy:

the persistence of severe pain or jaundice is an indication for surgical therapy

THANK YOU

